Acute Exacerbation of IPF

Pathogenesis and Clinical Approach

Harold R Collard, MD
Director, ILD Program
University of California San Francisco

6TH INTERNATIONAL MEETING ON PULMONARY RARE DISEASES AND ORPHAN DRUGS

Disclosures

- I have financial relationships with the following organizations:
  - Research Grants and Contracts:
    Boehringer Ingelheim, NIH/NHLBI, UCSF
  - Consulting:
    AstraZeneca/Medimmune, Bayer, Biogen, FibroGen, Five Prime, Genentech/InterMune, Genoa, Gilead, Mesoblast, Moerae Matrix, Patients Like Me, Pfizer, Promedior, Prometic, Pulmonary Fibrosis Foundation

Prologue

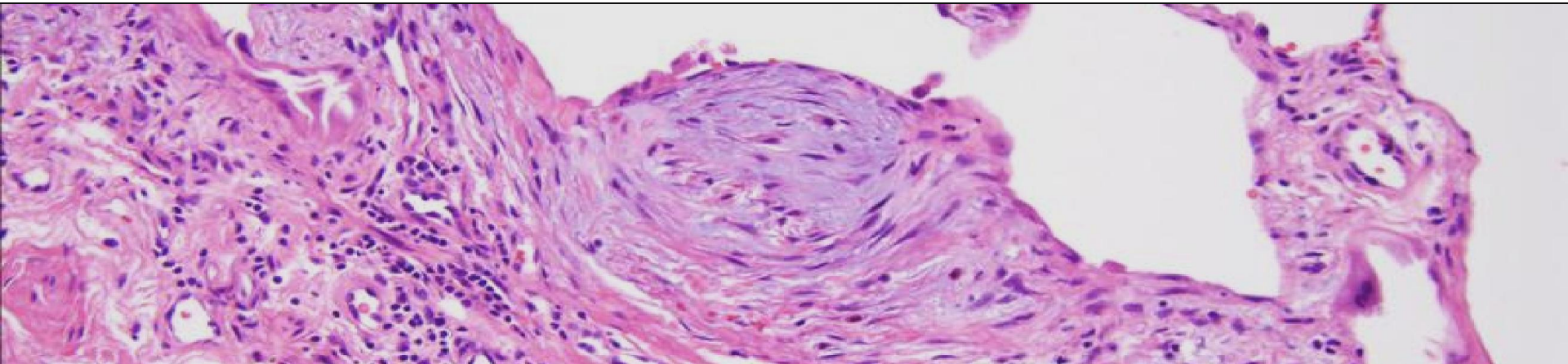

Interstitial Lung Disease

Exposure-related:
- Occupational
- Environmental
- Avocational
- Medication

Idiopathic interstitial pneumonia (IIP)

Connective tissue disease:
- Scleroderma
- Rheum. arth
- Sjogrens

Sarcoidosis

Other:
- Vasculitis/Diffuse alveolar hemorrhage (DAH)
- Langherhans cell histiocytosis (LCH)
- Eosinophilic pneumonias
- Neurofibromatosis
- LAM

Idiopathic pulmonary fibrosis (IPF)

Desquamative interstitial pneumonia (DIP)

Respiratory bronchiolitis interstitial lung dis. (RBILD)

Acute interstitial pneumonia (AIP)

Cryptogenic organizing pneumonia (COP)

Nonspecific interstitial pneumonia (NSIP)

Lymphocytic interstitial pneumonia (LIP)

Idiopathic pulmonary fibrosis (IPF)

- Idiopathic pulmonary fibrosis is defined as a specific form of chronic, progressive fibrosing interstitial pneumonia of unknown cause, occurring primarily in older adults, limited to the lungs, and associated with the histopathologic and/or radiologic pattern of usual interstitial pneumonia (UIP).

Raghu et al. AJRCCM 2011;183:788

UIP pattern on HRCT

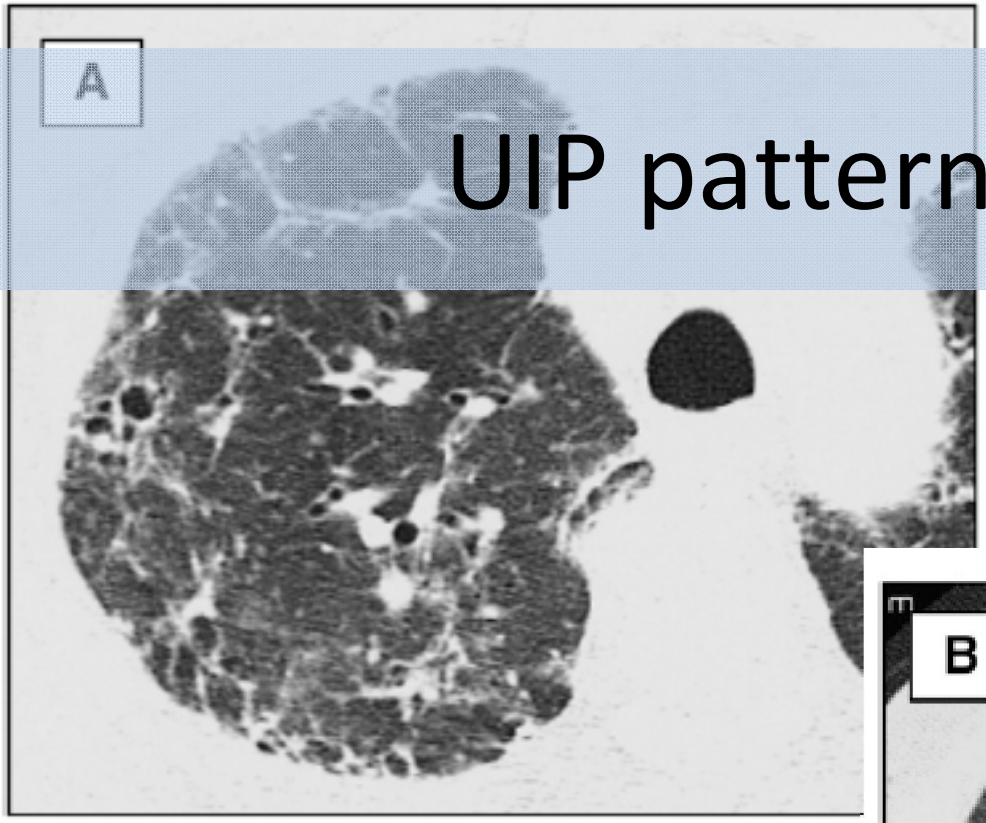

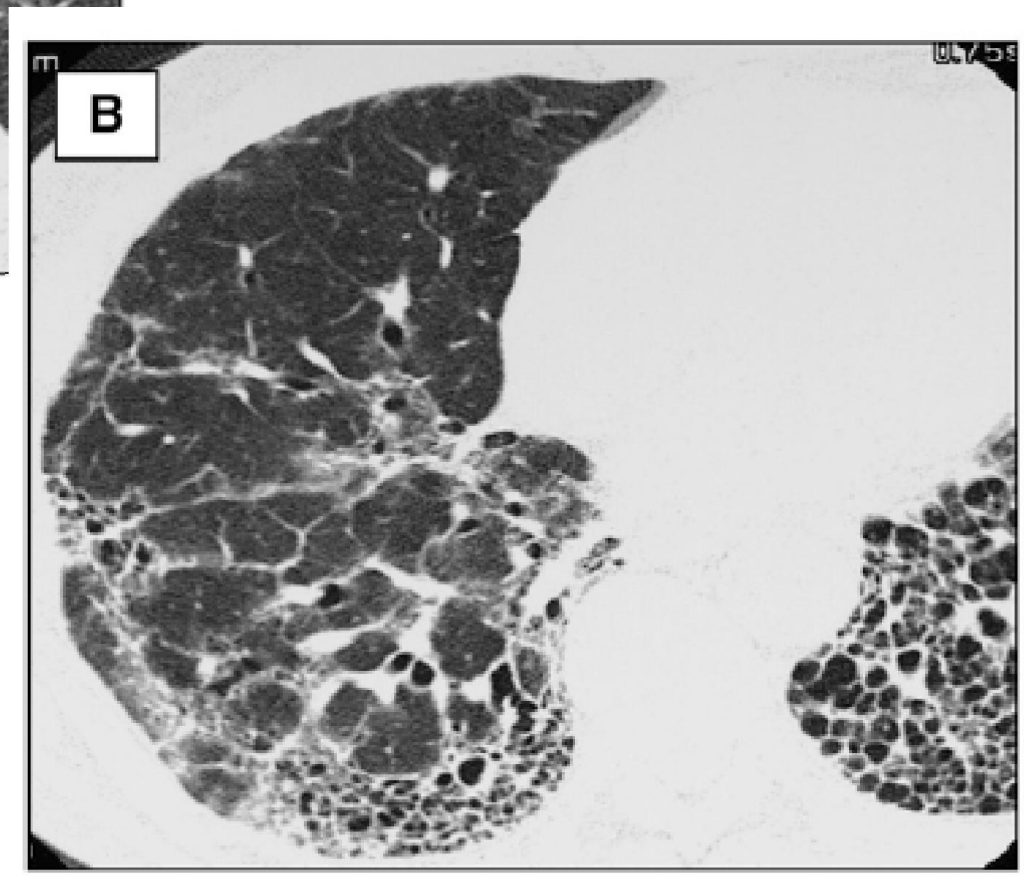

Sub-pleural, basal distribution; honeycombing; no atypical features

UIP pattern on lung biopsy

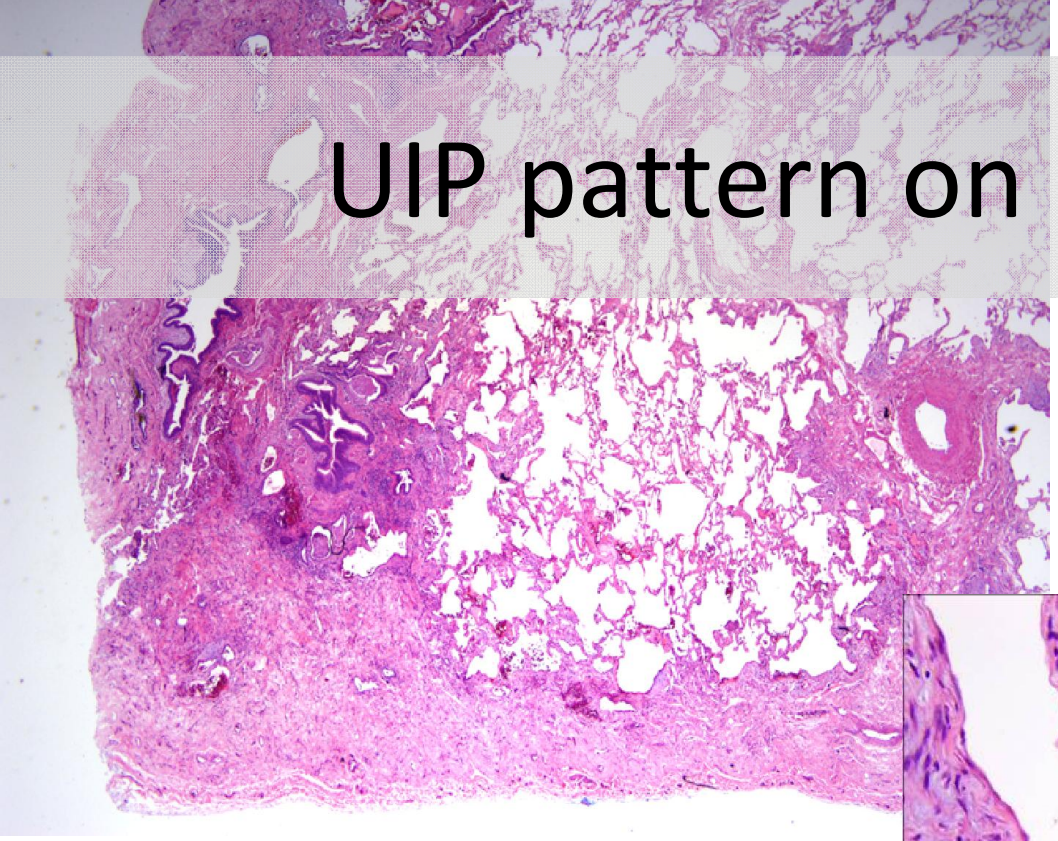

Honeycombing (not shown), peripheral fibrosis; normal lung; fibroplasia; no atypical features

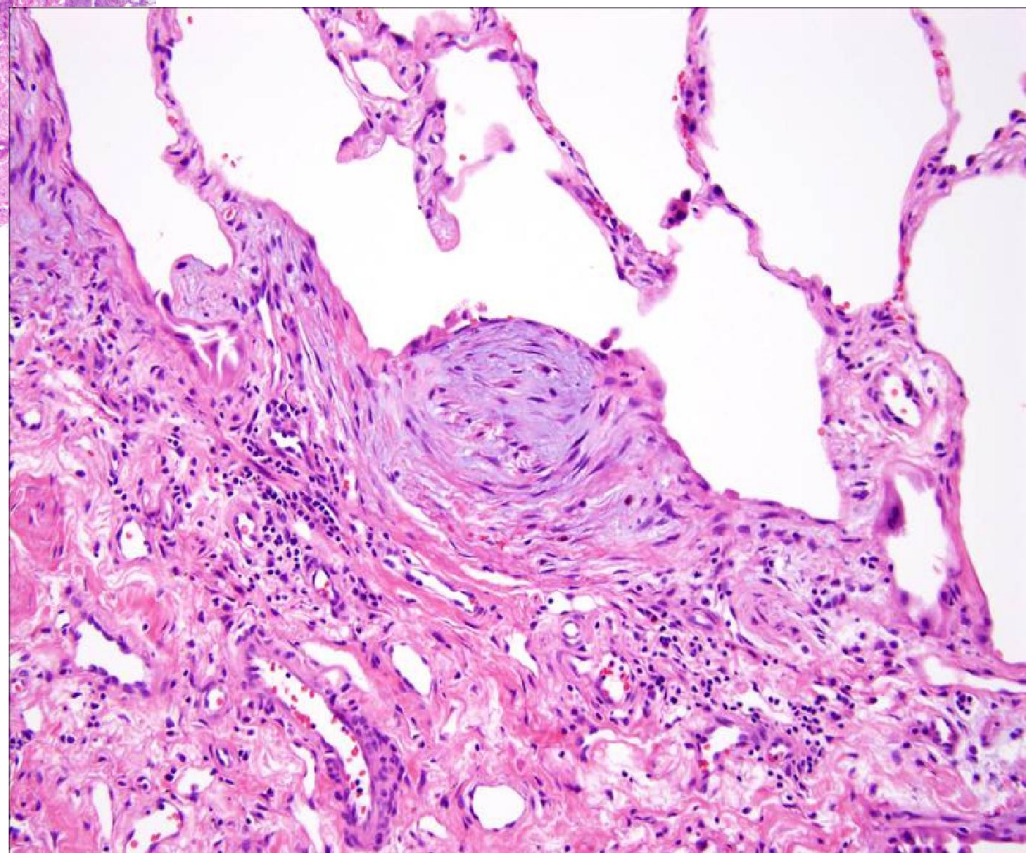

Part 1: Definitions and Epidemiology

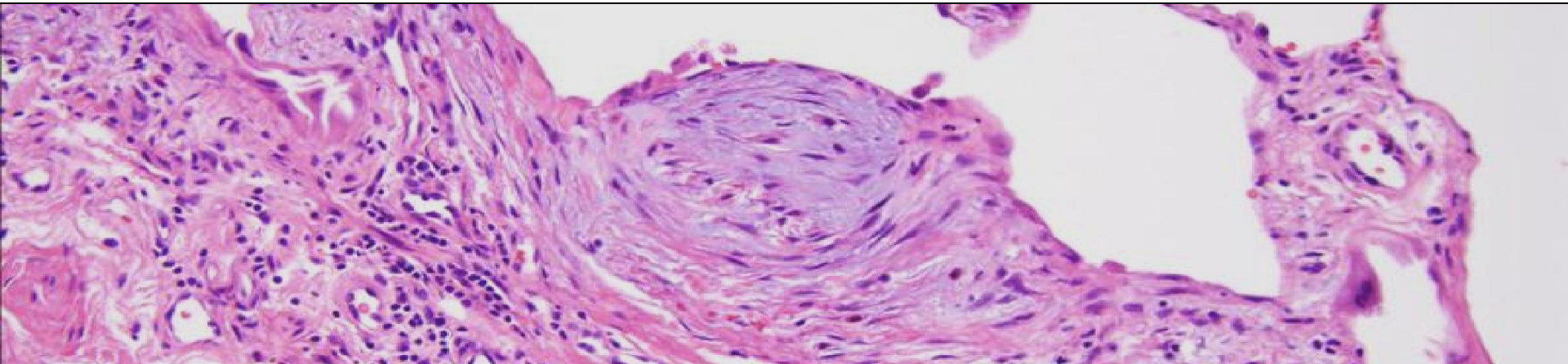

IPF Natural History

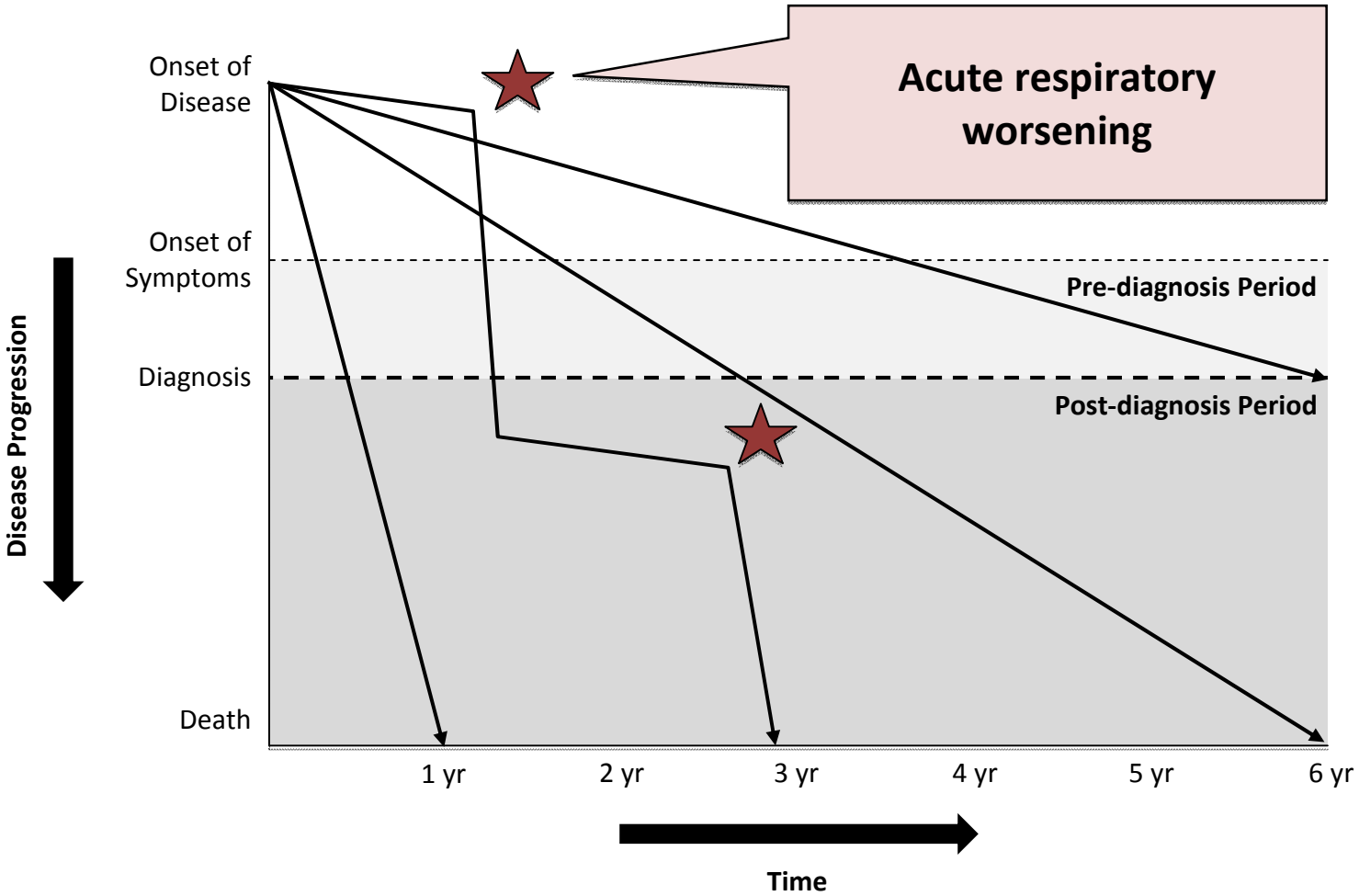

Ley et al. AJRCCM 2011;183:431

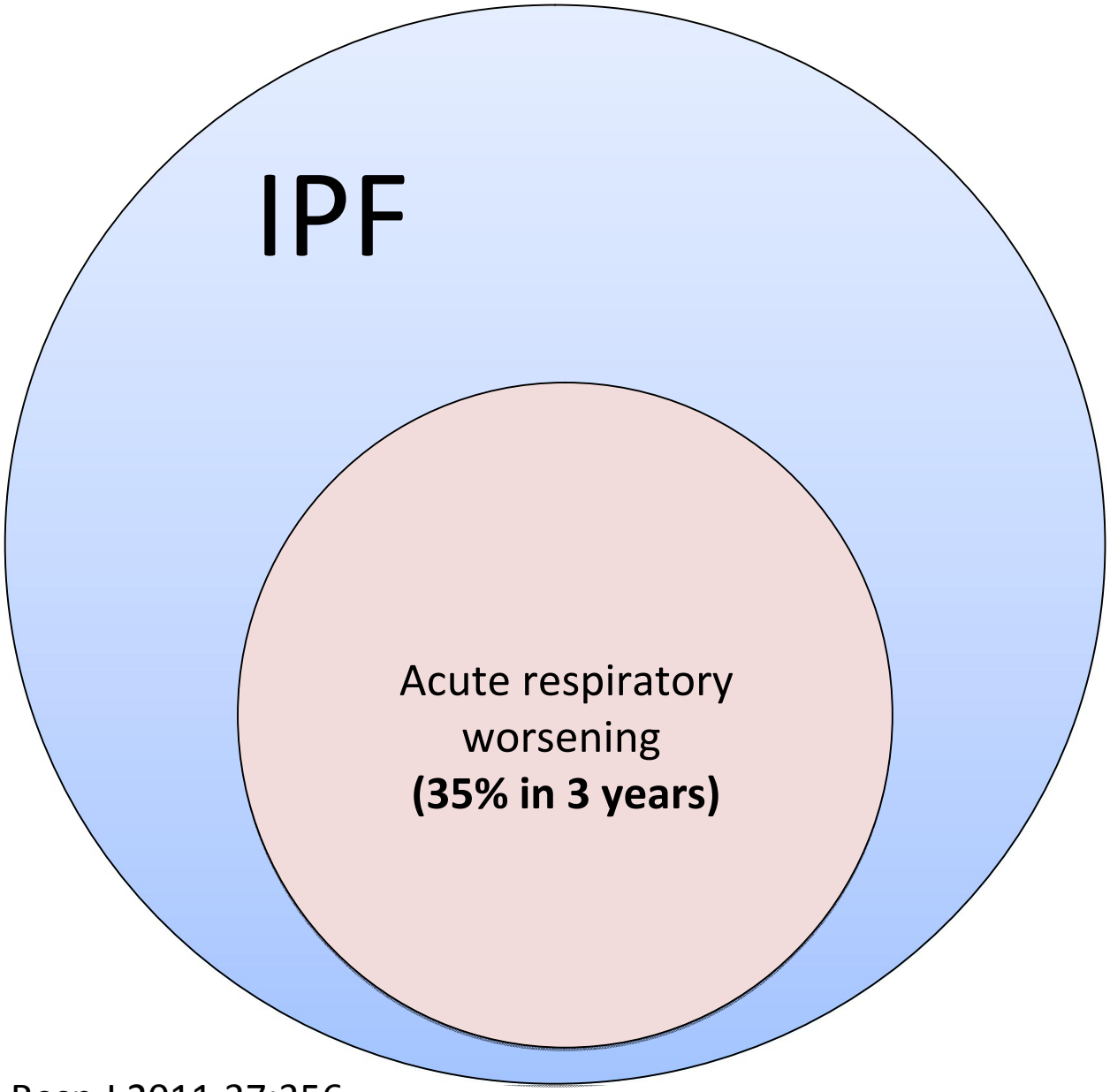

Song et al. Eur Resp J 2011;37:356

Acute Exacerbation (AEX)

- Acute exacerbation (AEX) = **idiopathic** acute respiratory worsening of IPF

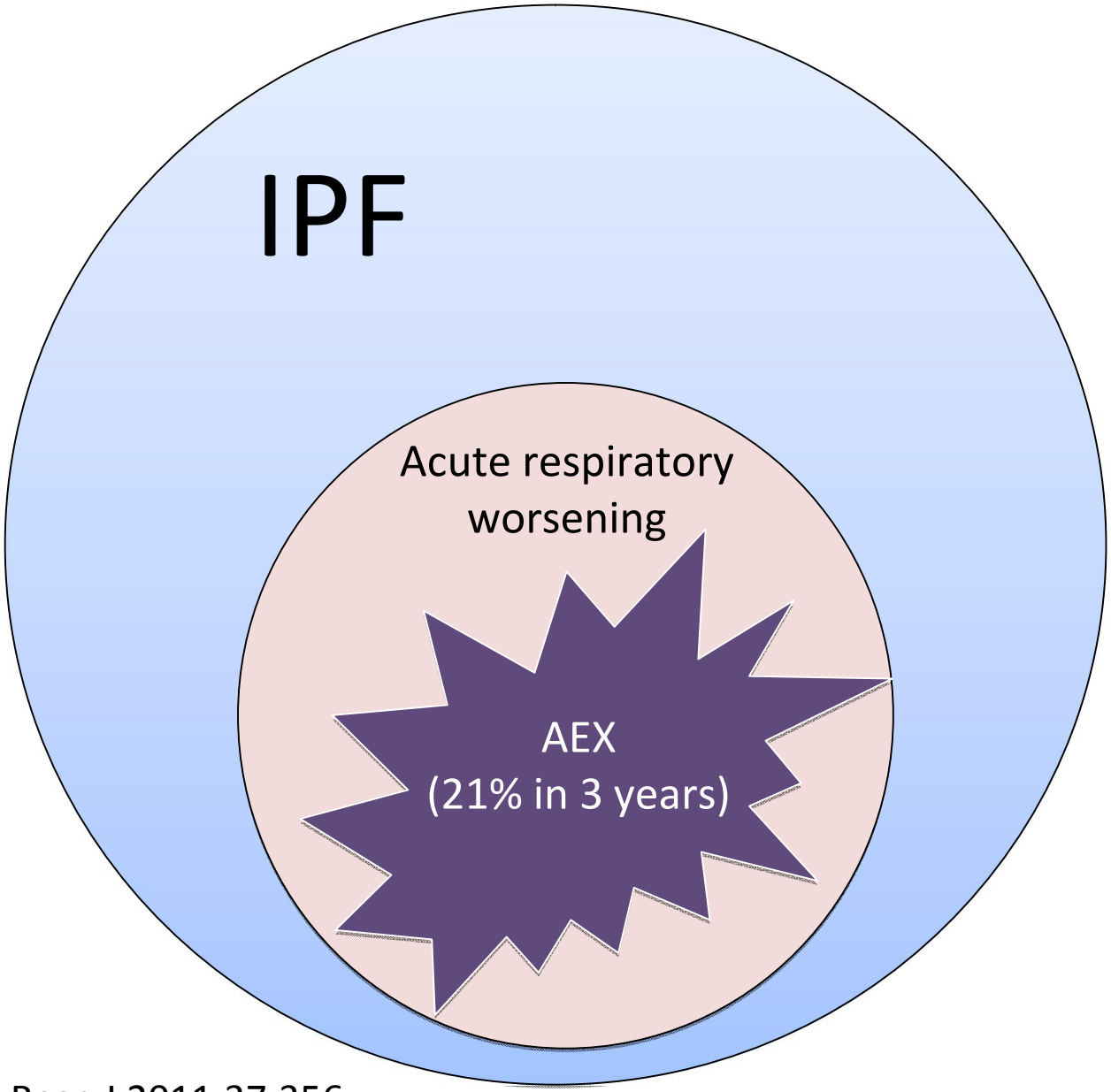

Song et al. Eur Resp J 2011;37:356

AEX: annual incidence

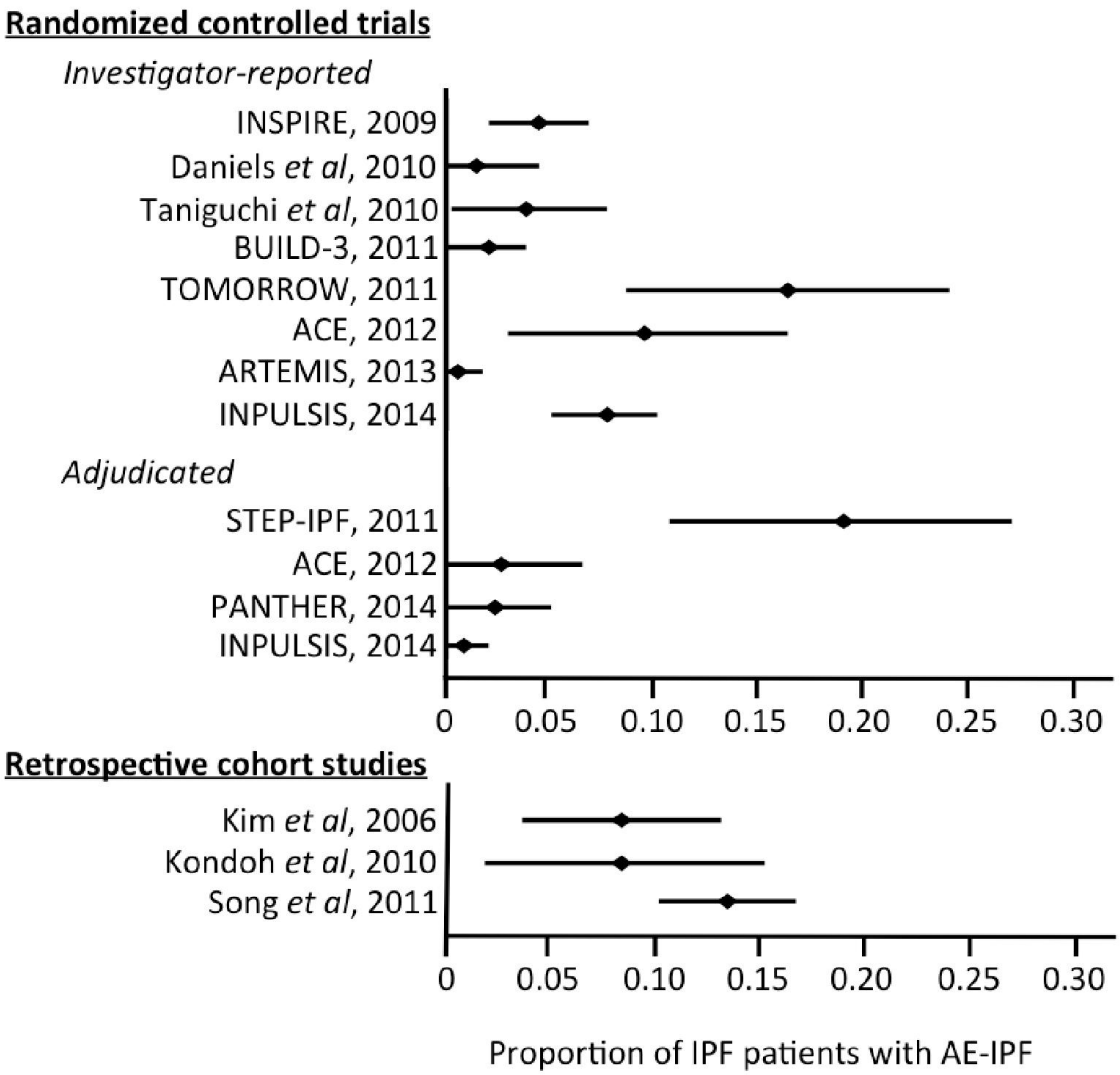

Ryerson, Cottin, Brown, Collard (unpublished)

AEX: annual incidence

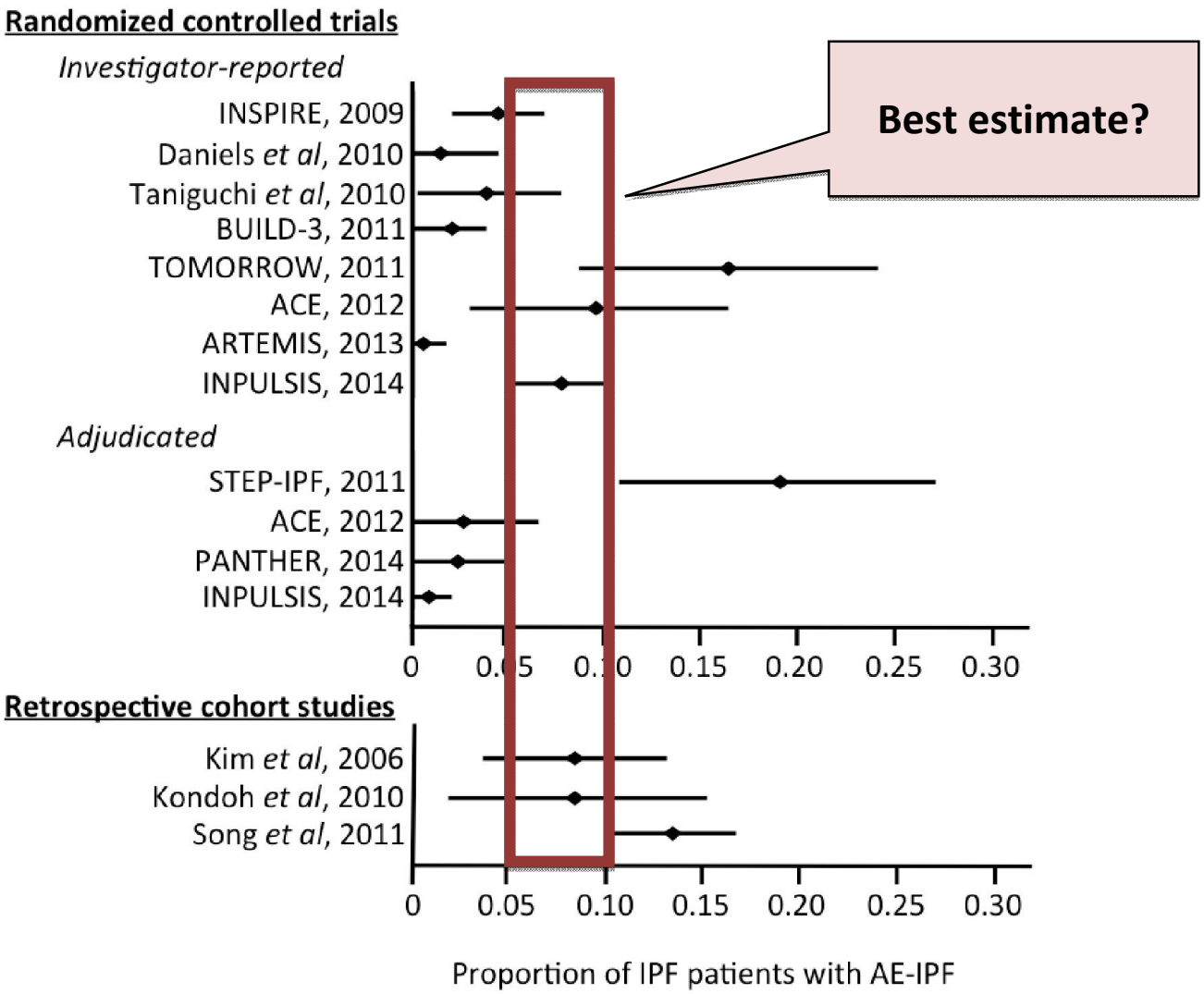

Ryerson, Cottin, Brown, Collard (unpublished)

Risk factors for Acute Exacerbation

- Disease severity is associated with risk

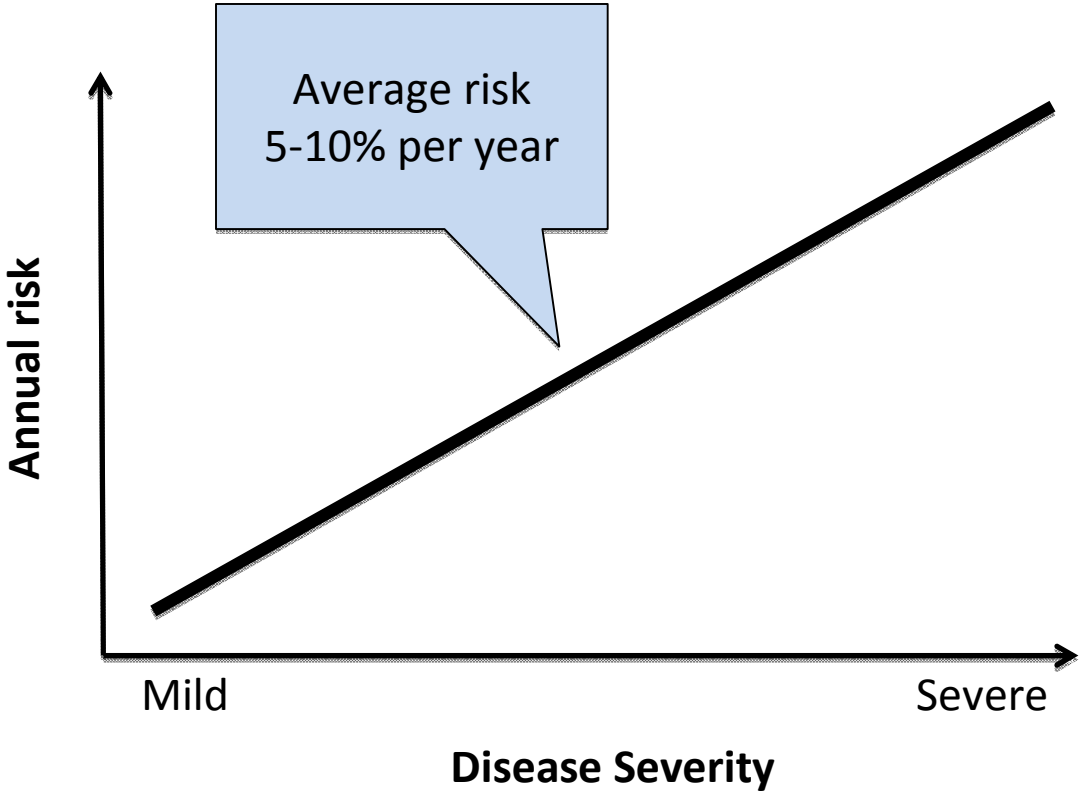

Specific risk factors:
- Lower FVC
- Lower DLCO?
- Worse dyspnea?
- Smoking?
- Ethnicity?

Collard Resp Res 2013;14:73 and Song Eur Resp J 2011;37:356

Short-term mortality is high

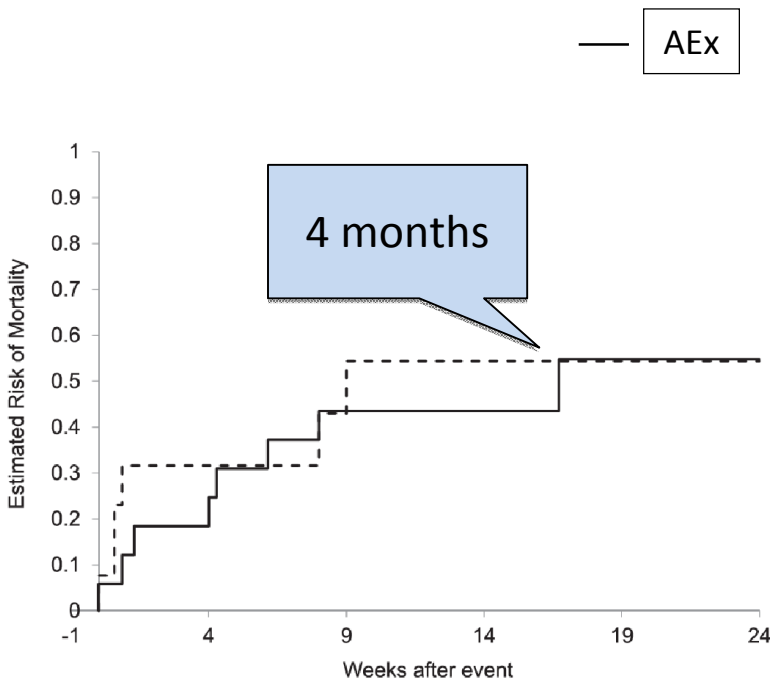

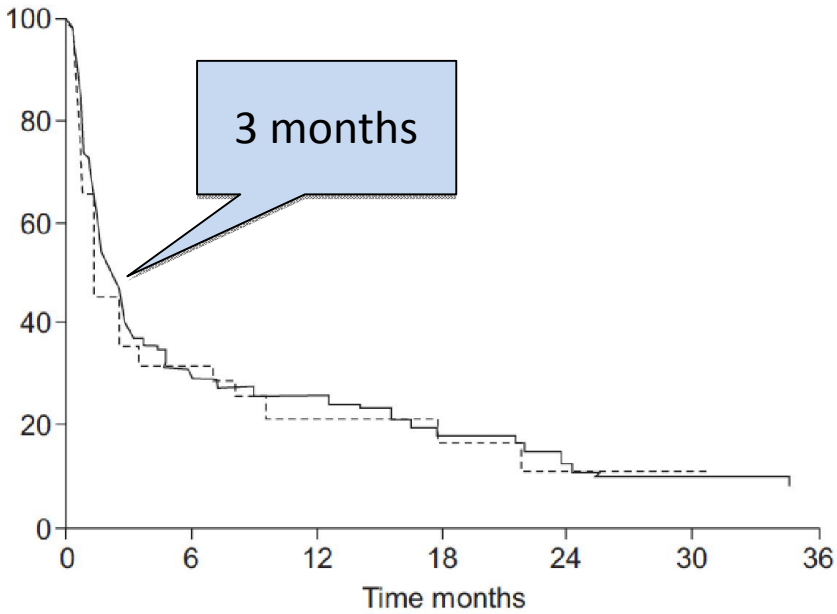

Collard Resp Res 2013;14:73 and Song Eur Resp J 2011;37:356

Part 2: Pathogenesis

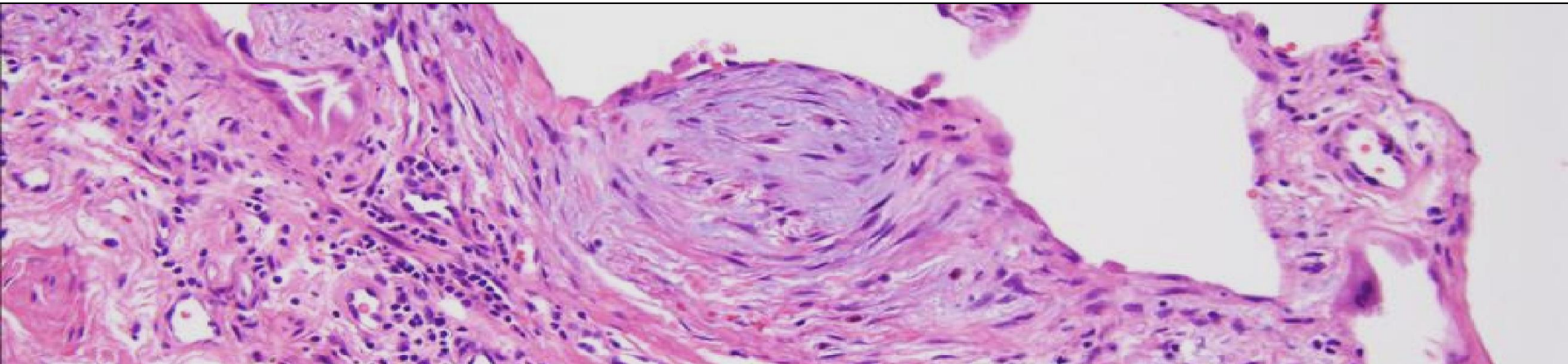

AEX Histopathology = DAD

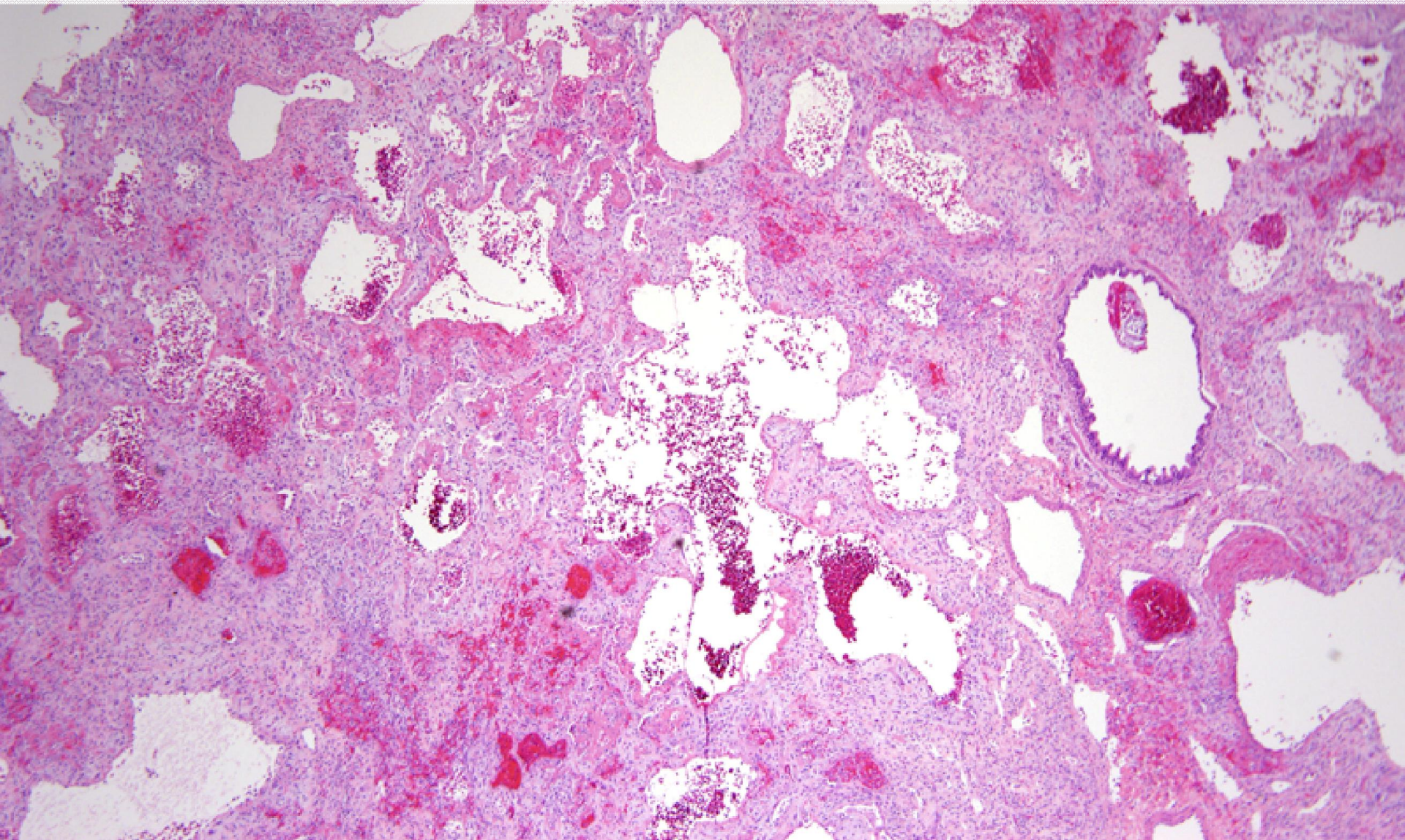

What causes DAD in IPF?

Intrinsic worsening of underlying disease?

Triggered by a secondary process?

Some potential triggers

- Viral infection
- Surgical procedure
- Microaspiration
- Ambient pollution

Trigger = respiratory viral infection

- A common respiratory virus was detected by deep sequencing in 9% of acute exacerbation BAL samples

Virus	Acute Exacerbation n = 43	Stable IPF n = 40	P value
Rhinovirus	2 (5%)	0 (0%)	0.49
Coronavirus	1 (2%)	0 (0%)	1.0
Parainfluenza	1 (2%)	0 (0%)	1.0
Adenovirus	0 (0%)	0 (0%)	--
Enterovirus	0 (0%)	0 (0%)	--
Influenza	0 (0%)	0 (0%)	--
Metapneumovirus	0 (0%)	0 (0%)	--
RSV	0 (0%)	0 (0%)	--

Wootton AJRCCM 2011;183:1698

Trigger = surgical procedure

- A small percentage of patients undergoing lung surgery appear to develop acute exacerbation post-operatively.

Study	Total IPF	AEX (%)	Comments
Kondoh et al. Resp Med 2006;10:1753	80	3 (4)	Exacerbation most pronounced in contralateral lung
Park et al. Eur J Cardiothorac Surg 2007;31:1115	140	2 (1)	More common was pre-existing acute exacerbation (i.e. seen on biopsy)

Trigger = microaspiration

- Eight of 24 (33%) patients with acute exacerbation had elevated pepsin levels in their BAL compared to stable IPF patients

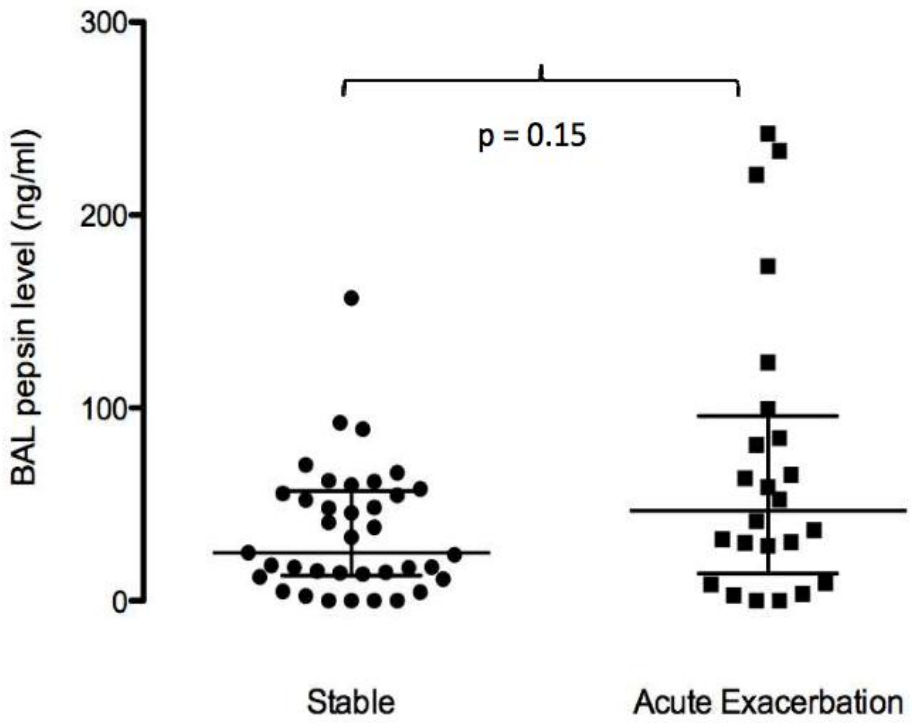

Lee ERJ 2012;39:352

Trigger = microaspiration

- Patients on PPI or H2B therapy had fewer acute exacerbations

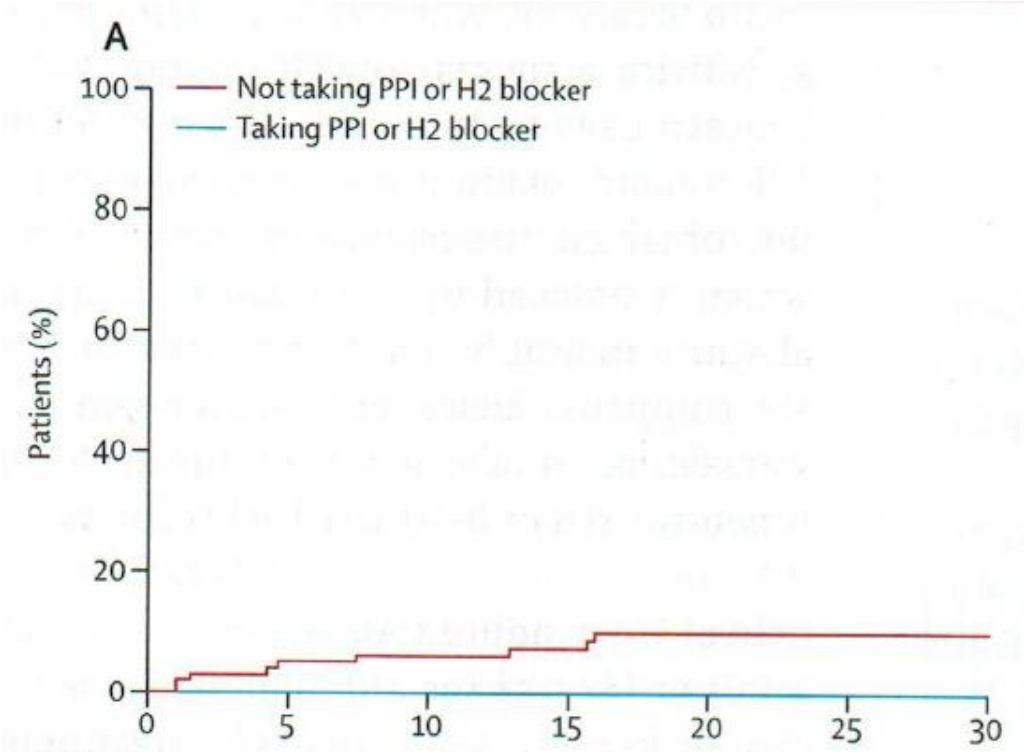

Lee Lancet Resp Med 2013;1:369

Trigger = ambient pollution

- Recent ozone and nitrogen dioxide (NO2) exposure was associated with an increased risk of acute exacerbation

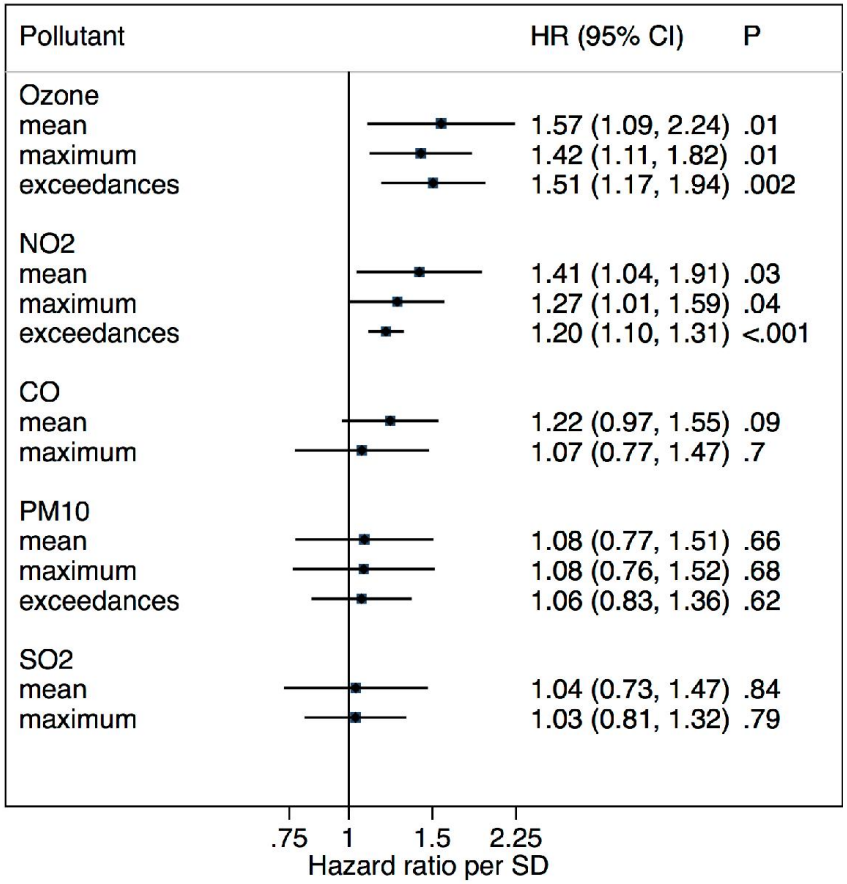

Johannson ERJ 2014;43:1124

What causes DAD in IPF?

Intrinsic worsening of underlying disease?

Triggered by a secondary process?

Part 3: Clinical Approach

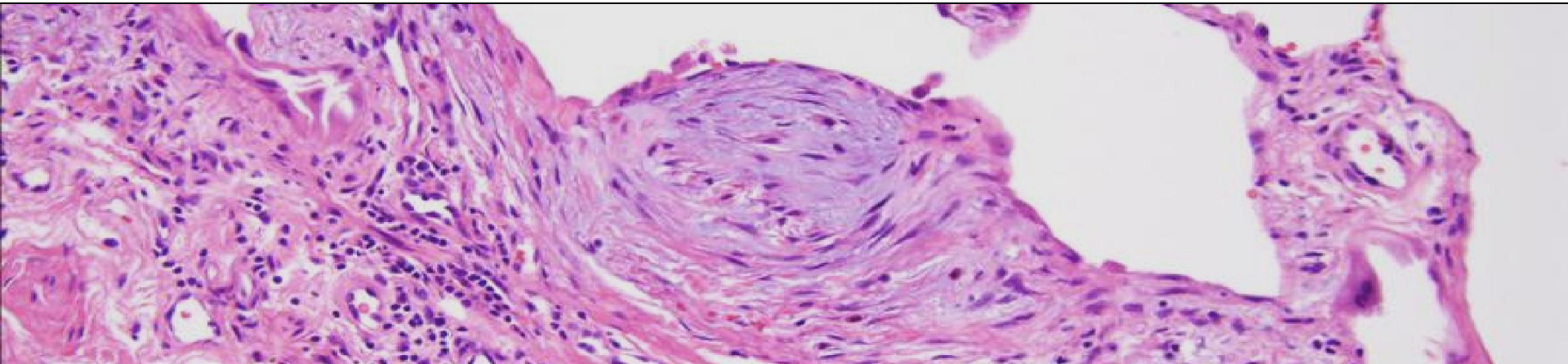

AEX: Diagnostic Criteria

Must have all four:

- Unexplained worsening of dyspnea over < 30 days
- New bilateral ground glass or consolidation on HRCT
- No evidence of pulmonary infection by ET aspirate/BAL
- Exclusion of other known causes of acute worsening

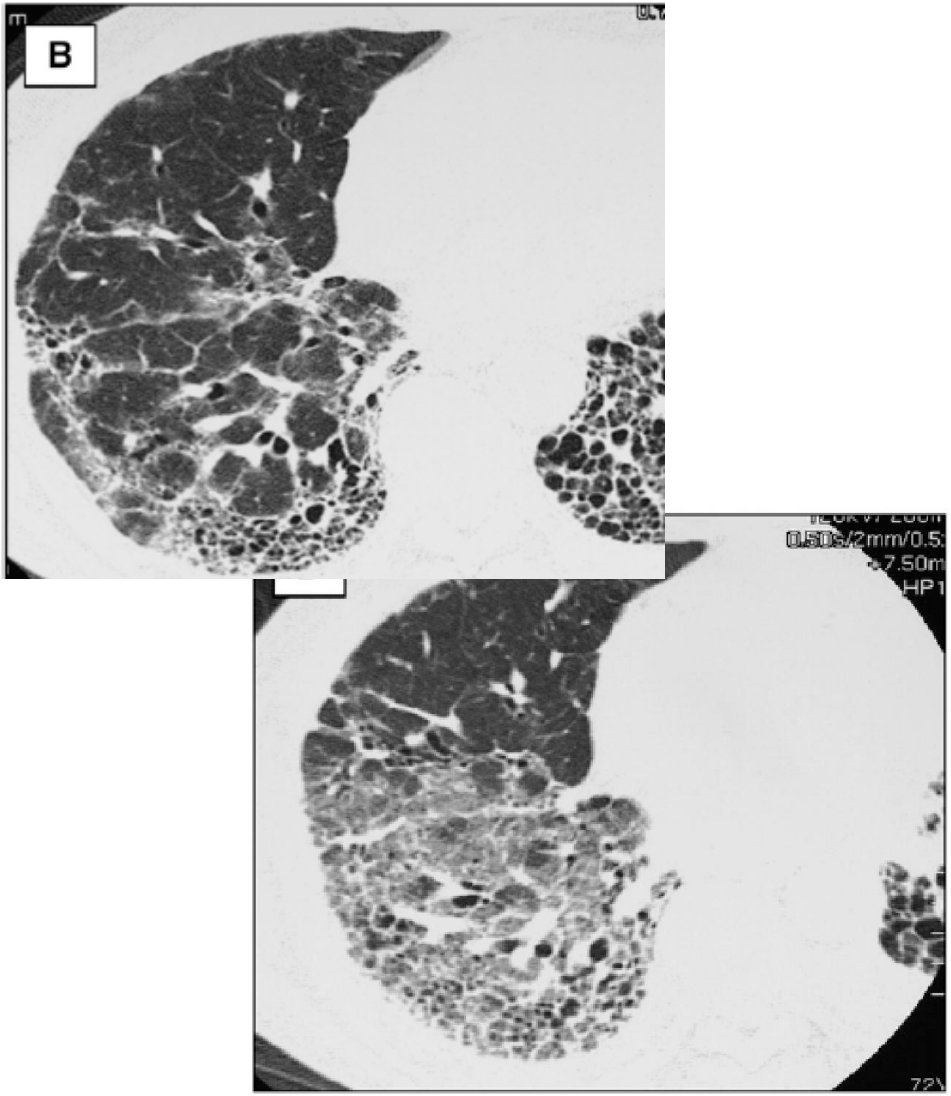

Collard AJRCCM 2007;176:636

AEX: Diagnostic Criteria

Must have all four:

- Unexplained worsening of dyspnea over < 30 days
- New bilateral ground glass or consolidation on HRCT
- No evidence of pulmonary infection by ET aspirate/BAL
- Exclusion of other known causes of acute worsening

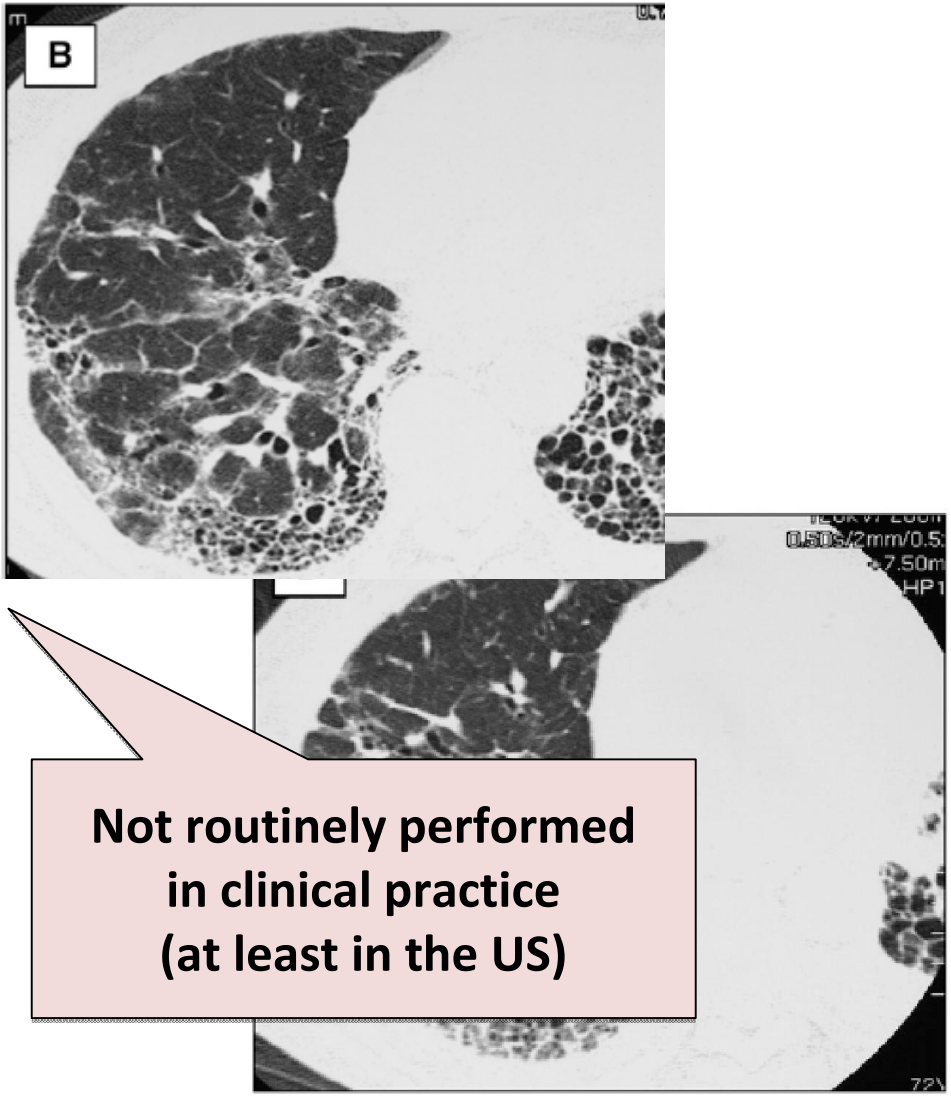

Not routinely performed in clinical practice (at least in the US)

Collard AJRCCM 2007;176:636

STEP-IPF trial: Acute worsenings

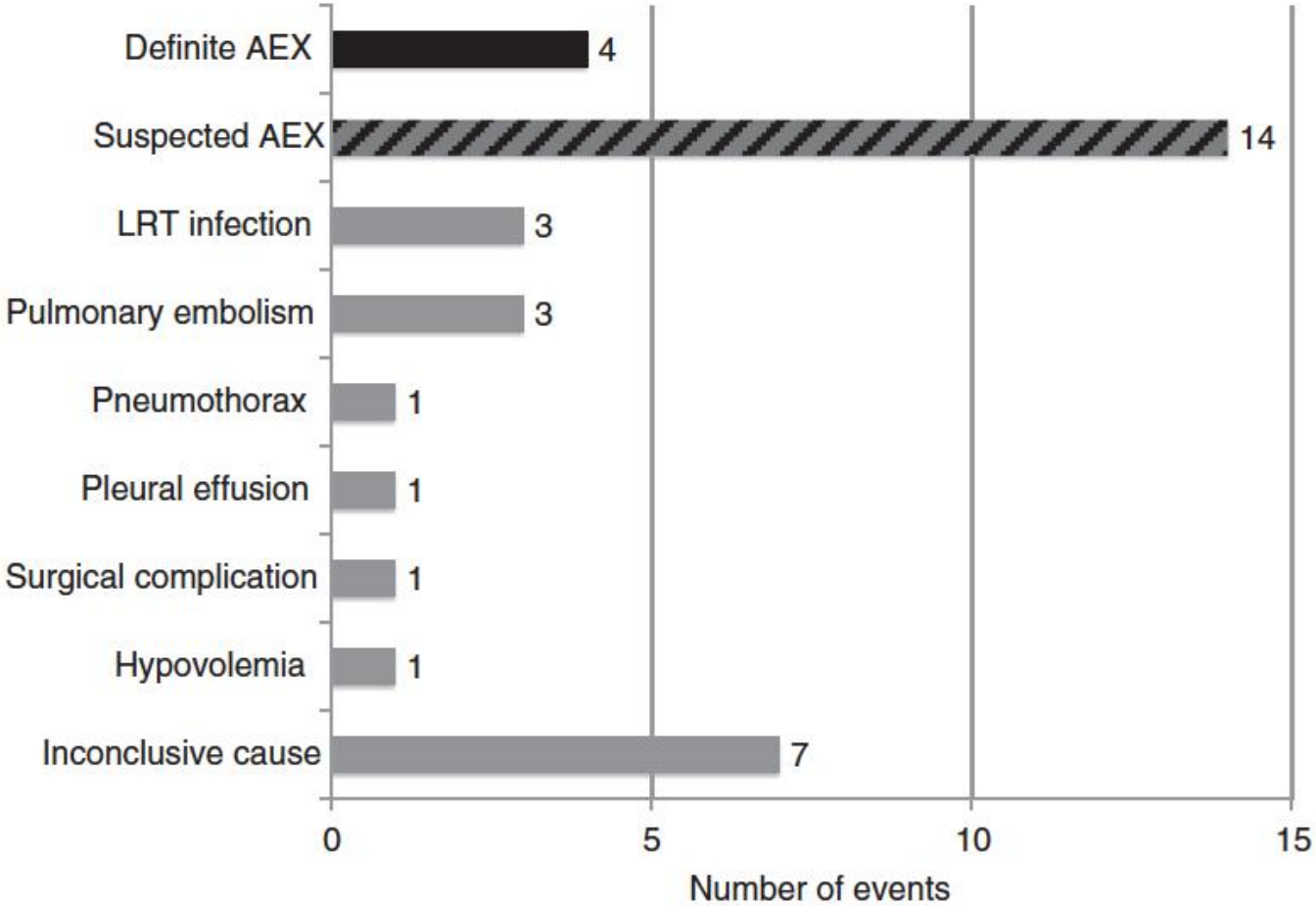

Collard Resp Res 2013;14:73

STEP-IPF trial: Suspected AEX

Case	Unexplained acute worsening	HRCT with bilateral GGO	No infection by microbiology	Other causes excluded
Suspected 1	OK	OK	Not performed	OK
Suspected 2	OK	OK	Not performed	OK
Suspected 3	OK	OK	Not performed	OK
Suspected 4	OK	OK	Not performed	OK
Suspected 5	OK	No GGO	OK	OK
Suspected 6	OK	Not performed	OK	OK
Suspected 7	OK	Not performed	OK	OK
Suspected 8	OK	Not performed	OK	OK
Suspected 9	OK	Not performed	Not performed	OK
Suspected 10	OK	Not performed	Not performed	OK
Suspected 11	OK	Not performed	Not performed	OK
Suspected 12	OK	Not performed	Not performed	OK
Suspected 13	OK	Not performed	Not performed	OK
Suspected 14	OK	Not performed	Not performed	OK

Collard Resp Res 2013;14:73

AEX: Management (1)

- Corticosteroids
  - **"The majority of patients with acute exacerbation of IPF should be treated with corticosteroids."**
  - High value placed on anecdotal reports and the high mortality of acute exacerbation
  - No recommended dose or duration
- Other approaches: cyclosporine A, heparin, polymixin B column filtration
- Mechanical ventilation

Raghu AJRCCM 2011;183:788

AEX: Management (2)

- Supportive care is the mainstay
- Prevention?
  - Vaccination for influenza and pneumococcus
  - Avoidance of sick contacts
  - Avoidance of unnecessary surgery/mechanical ventilation
  - Treatment of comorbidities (GERD, OSA)
  - Treatment of IPF

Epilogue

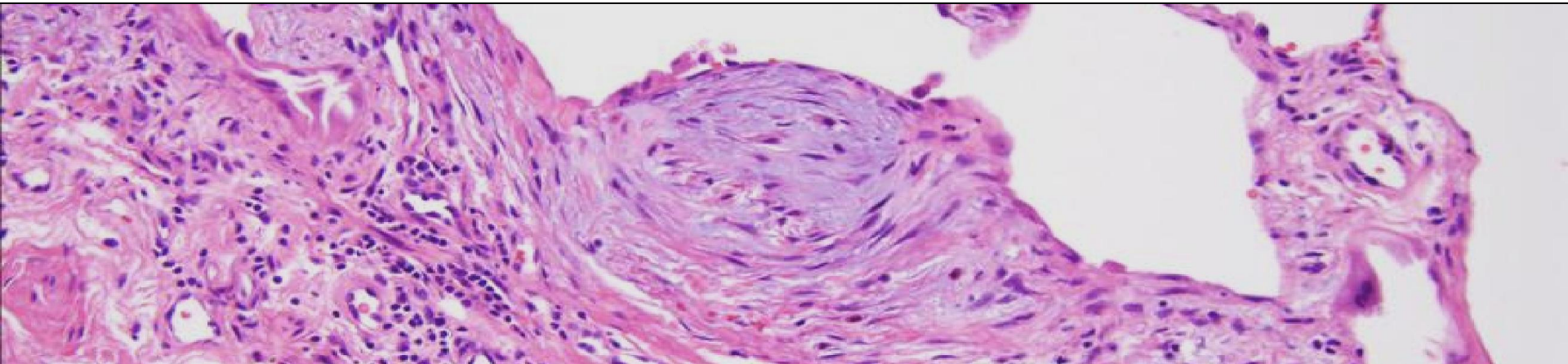

Rethinking acute exacerbation

- I believe many (if not) all acute exacerbations are triggered by some secondary process.
  - Early studies support this hypothesis
  - Outcomes data suggests that acute worsenings of known and unknown cause have similar disease behavior
  - It simplifies the pathobiological construct
- The central pathobiological observation in acute exacerbation is the presence of DAD.

Rethinking acute exacerbation

- Based on this, I believe that the current definition for acute exacerbation needs revision.

Rethinking acute exacerbations

- **Current AEX definition:** Idiopathic acute respiratory worsening of IPF

- **Proposed AEX definition:** Acute respiratory worsening of IPF resulting in the presence of diffuse alveolar damage

As proposed, pathobiology, not etiology, would define AEX

Ryerson Curr Opin Resp Med 2014;20:436

Rethinking acute exacerbations

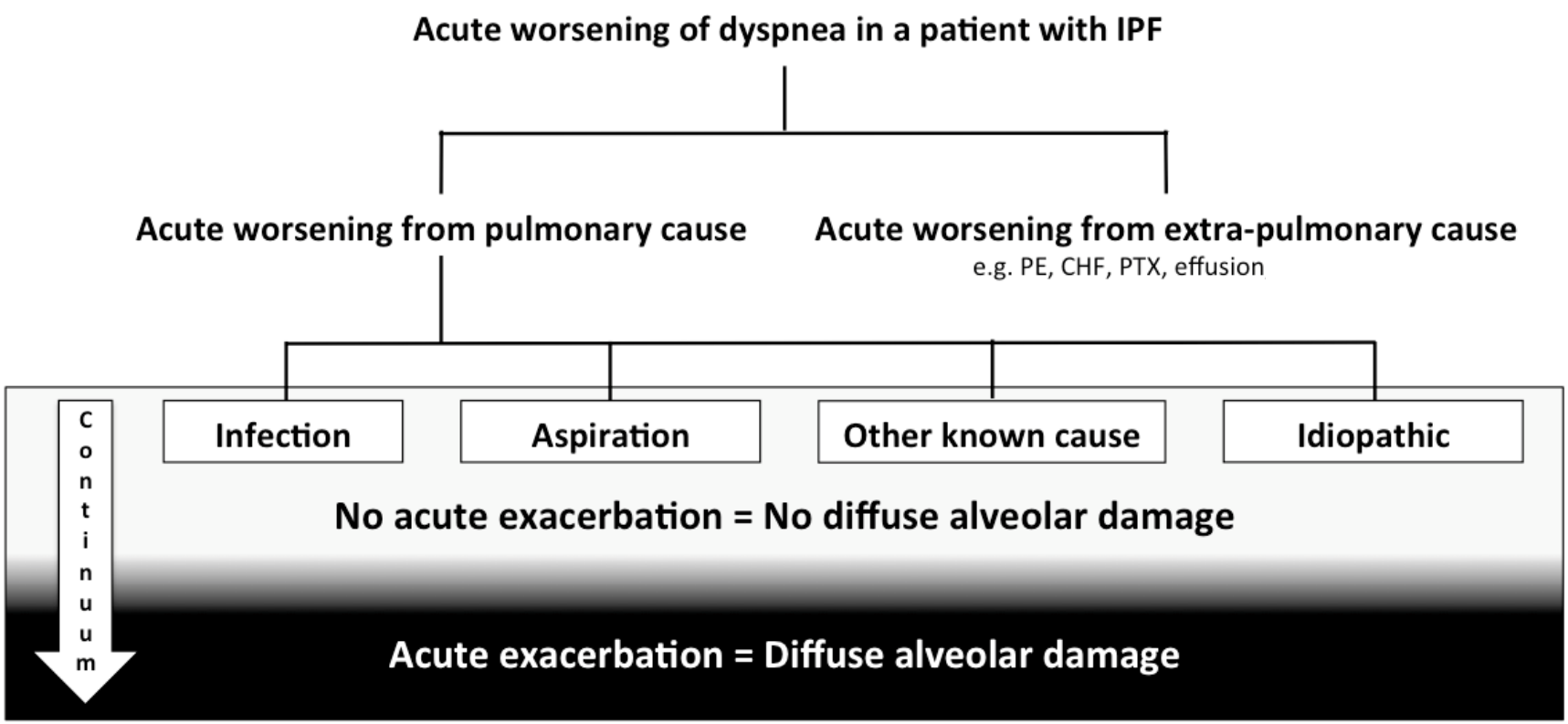

Ryerson, Cottin, Brown, Collard (unpublished)

Summary

- Acute exacerbations (AEXs) are defined as idiopathic acute respiratory worsenings of IPF
- AEXs are infrequent but important clinical events with high short-term mortality
- AEXs are characterized by the presence of diffuse alveolar damage (DAD)
- The management of AEX is primarily supportive, but corticosteroids are recommended in the majority of cases

Acute Exacerbation of IPF

Pathogenesis and Clinical Approach

Harold R Collard, MD
Director, ILD Program
University of California San Francisco

6TH INTERNATIONAL MEETING ON PULMONARY RARE DISEASES AND ORPHAN DRUGS