

# **IPF - Inquadramento clinico**

**Sergio Harari**  
**Unità Operativa di Pneumologia**  
**UTIR – Servizio di Fisiopat. Resp.**  
**e Emodinamica Polmonare**  
**Ospedale S. Giuseppe, Milano**

# Clinical Classification

## Diffuse parenchymal lung diseases

### Exposure-related:

- occupational
- environmental
- medication

### Idiopathic interstitial pneumonias

### Idiopathic pulmonary fibrosis

### Connective tissue Disease:

- Scleroderma
- Rheum. Arthritis
- Sjogren
- UCTD

### Other:

- Sarcoidosis
- Vasculitis/DAH
- LCH
- LAM
- PAP
- Eosinophilic pneumonia
- Neurofibromatosis
- Chronic aspiration
- Inflammatory bowel disease

Desquamative interstitial pneumonia

Acute interstitial pneumonia

Non-specific interstitial pneumonia

Respiratory bronchiolitis interstitial lung disease

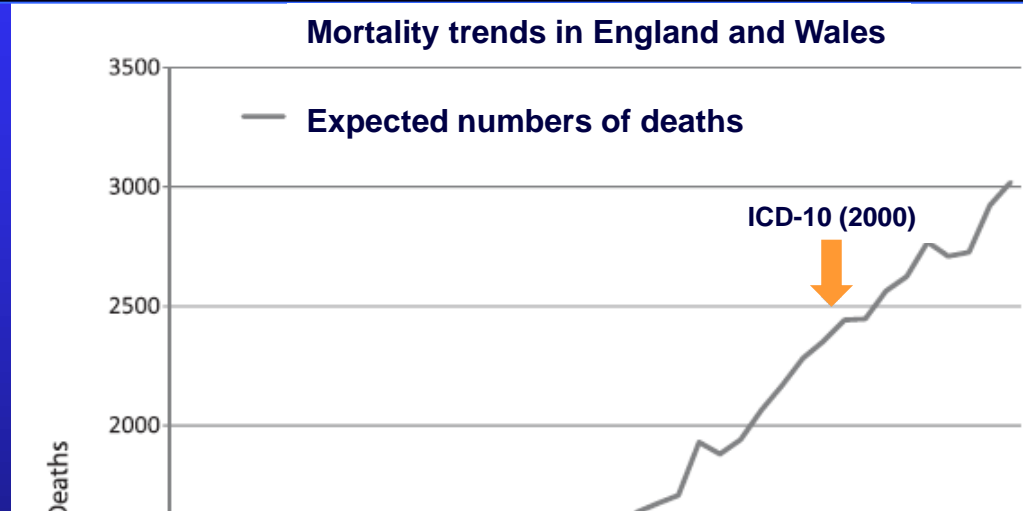
Cryptogenic organising pneumonia

Lymphocytic interstitial pneumonia

# *The rising incidence of idiopathic pulmonary fibrosis in UK*

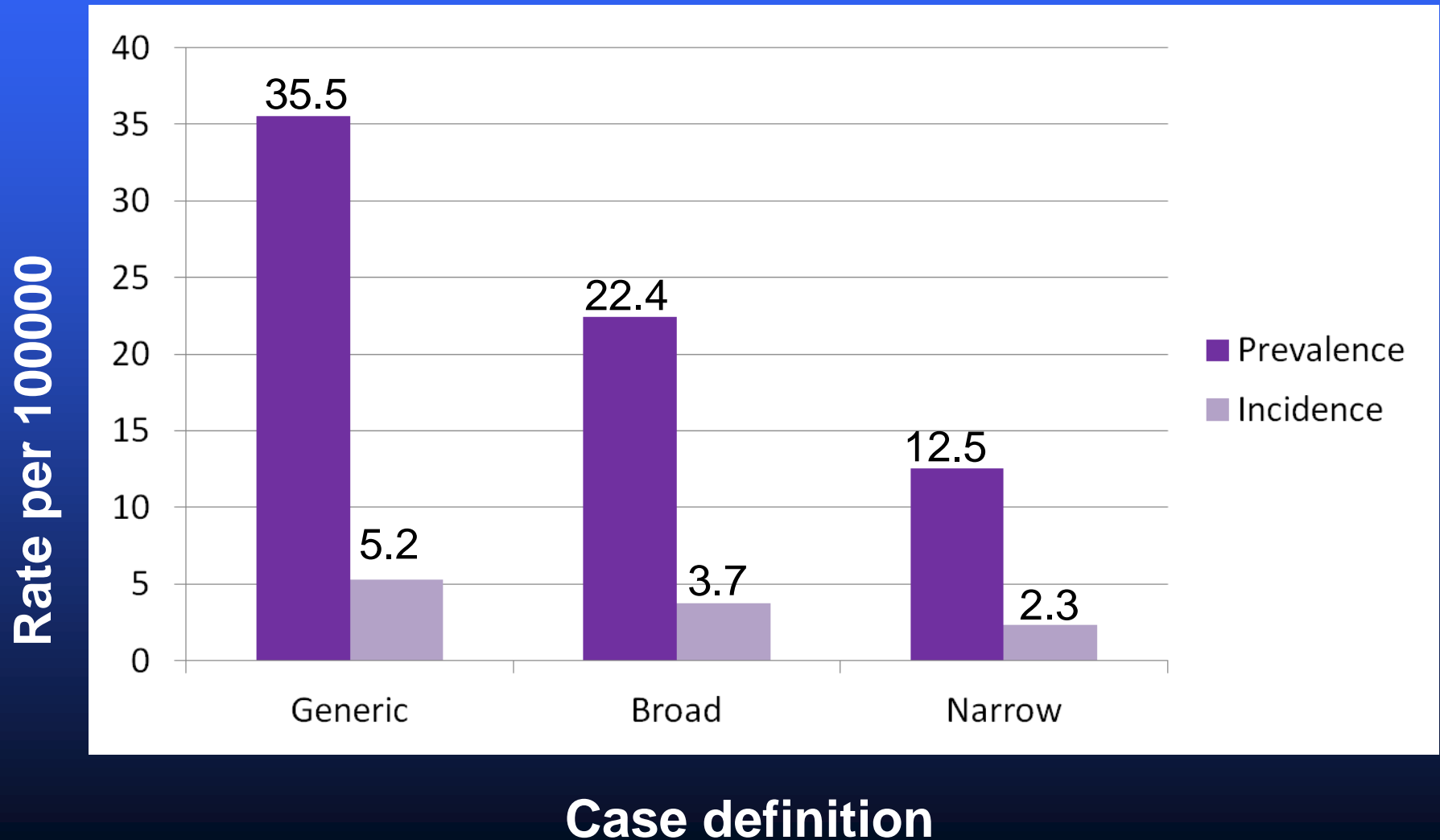
*Navaratnam V et al. Thorax 2011;66:462*

- ◆ 15000 people in the UK have a diagnosis of IPF-CS
- ◆ each year, 5000 new cases of IPF
- ◆ each year, 5000

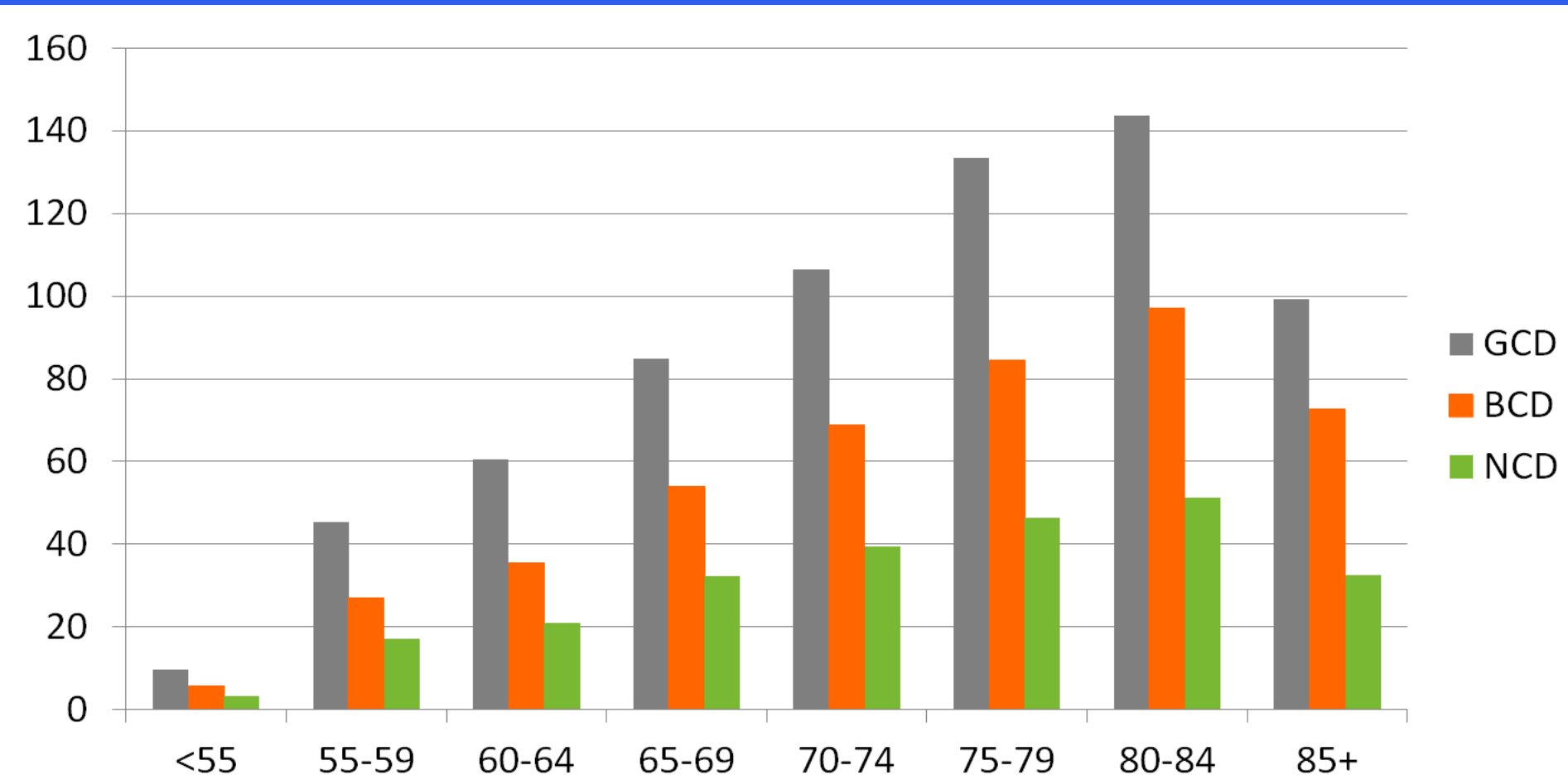


**“This means that in the UK, more people will die each year from IPF-CS than from ovarian cancer, lymphoma, leukaemia, mesothelioma or kidney cancer”**

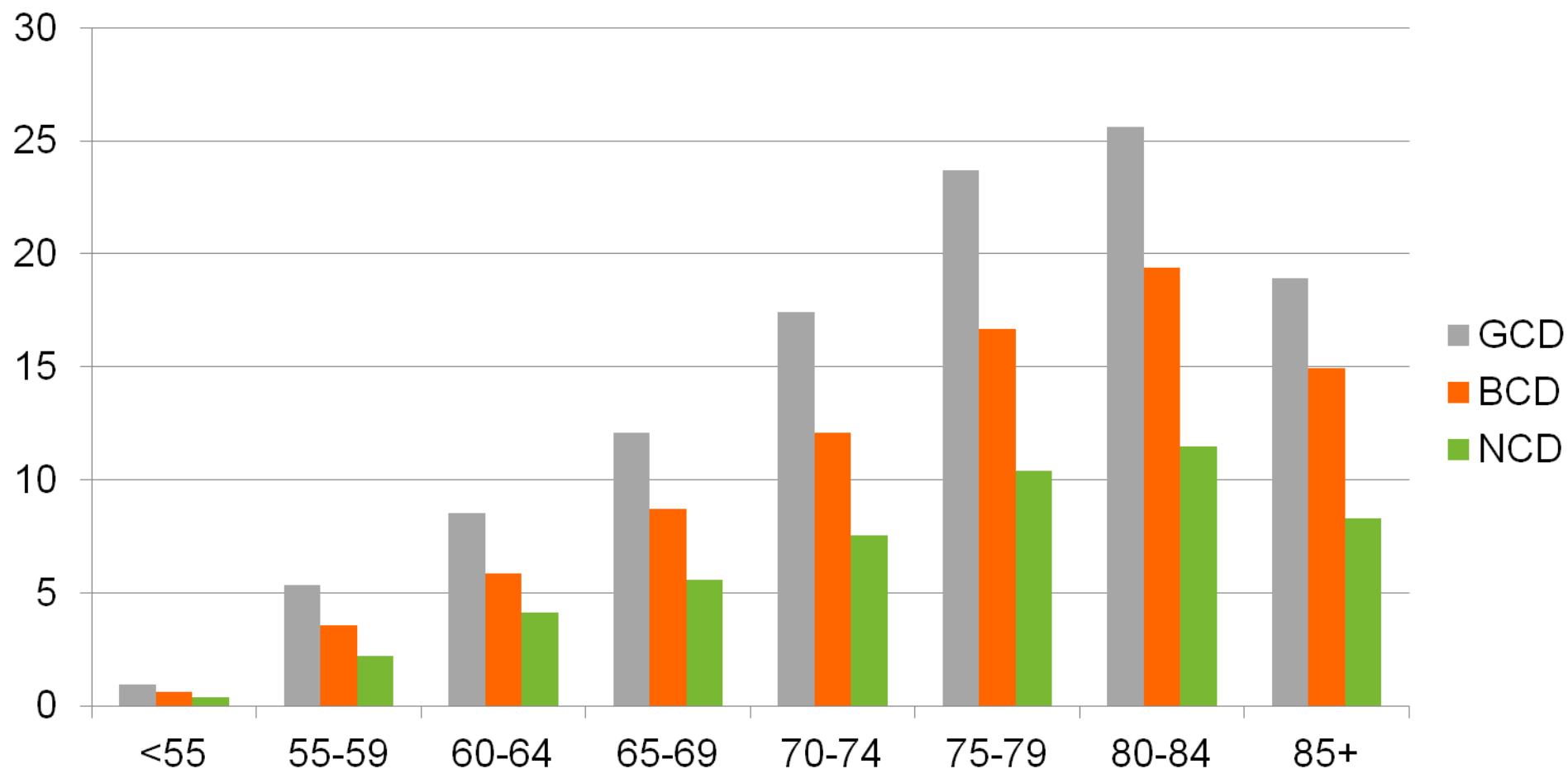
**Prevalence and incidence rate** (x100,000 person-years) according to the three case definitions, during the period 2005-2010 in Lombardy



*Estimates of the mean annual standardized prevalence rate (x100,000 person-years) according to the three case definitions, during the period 2005-2010*



*Estimates of the mean annual standardized incidence rate (x100,000 person-years) according to the three case definitions, during the period 2005-2010*



# *New definition of IPF*

- ◆ IPF is a specific form of **progressive** fibrosing interstitial pneumonia
- ◆ Unknown cause
- ◆ Occurring in older adults
- ◆ Limited to the lungs
- ◆ Associated with a histological **and/or radiological** pattern of usual interstitial pneumonia (UIP)

# *Importance of early diagnosis of IPF*

- ◆ Begin evaluation for lung transplant earlier
- ◆ Allows for earlier referral and enrollment in clinical trials (which are generally limited to patients with mild to moderate disease)
- ◆ Emerging evidence regarding response to therapy
- ◆ Exclude other more treatable diseases



# *Delayed access and survival in Idiopathic Pulmonary Fibrosis*

## *A Cohort study*

*Lamas DJ et al. Am J Respir Crit Care Med 2011; 184: 842*

- ◆ Our results suggest that the recognition (or suspicion) of IPF should prompt early referral to a

At present, ILD screening efforts are limited to those with known risk factors for ILD or those with a history of familial IPF. Innovative studies of circulating biomarkers and quantitative imaging methods may hold the key to more accurately identifying early disease

# *Don't stop with "pulmonary fibrosis"*

- Reason for a specific diagnosis:
  - ❖ many forms are treatable
  - ❖ treatments depend on diagnosis
  - ❖ prognosis varies
  - ❖ clinical trial eligibility requirements

*In idiopathic interstitial  
pneumonia, diagnosis is  
prognosis*

# *Approach to the diagnosis of IPF*

## *Clinical*

- History
- Physical
- Laboratory
- PFTs

## *Radiology*

- Chest X-ray
- HRCT

## *Pathology*

- Surgical lung biopsy

Primary care  
physicians

Pulmonologists

Radiologists

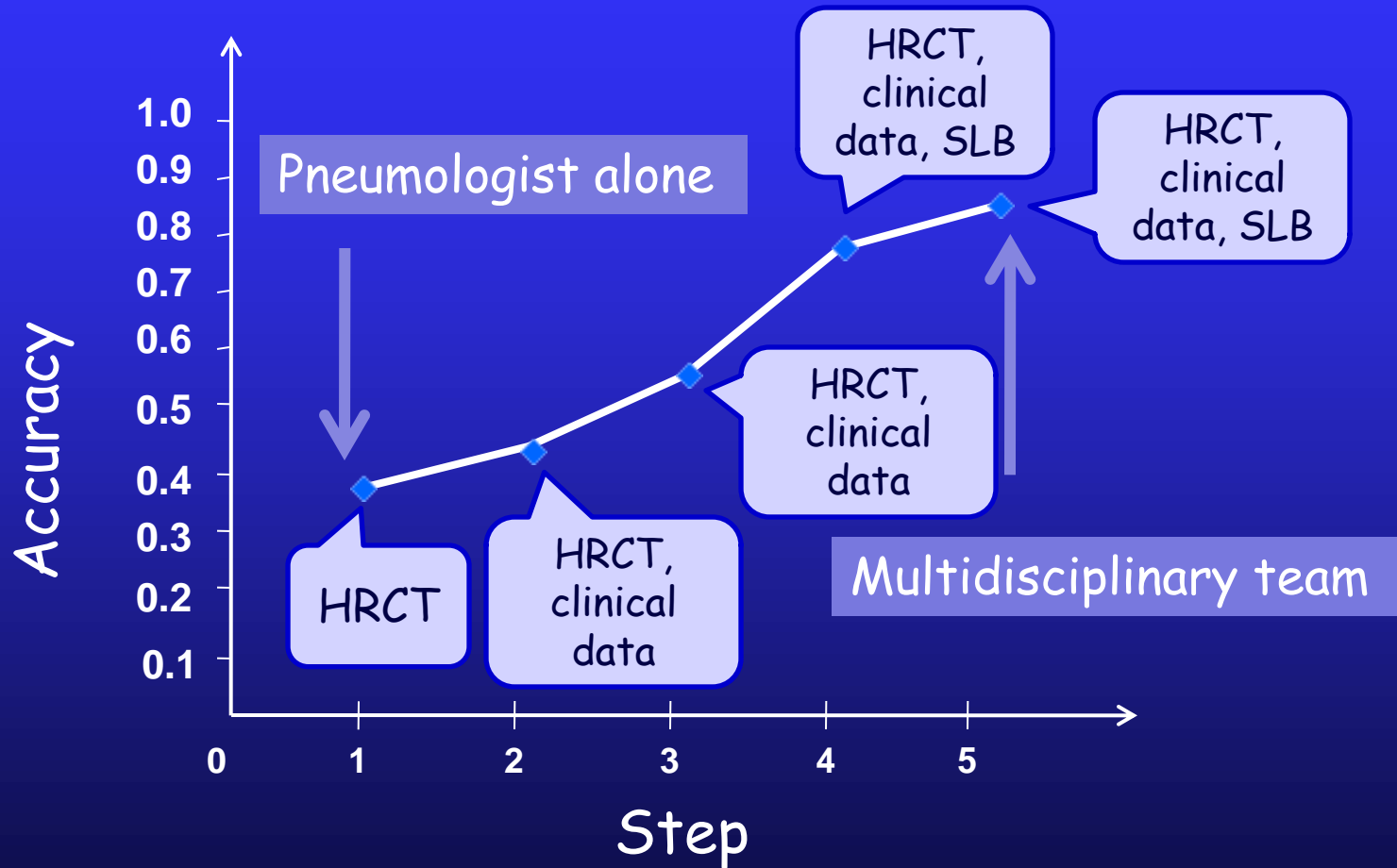
Pathologists

Multidimensional and multidisciplinary

The gold-standard of IIP diagnosis

# Diagnosis is multidisciplinary

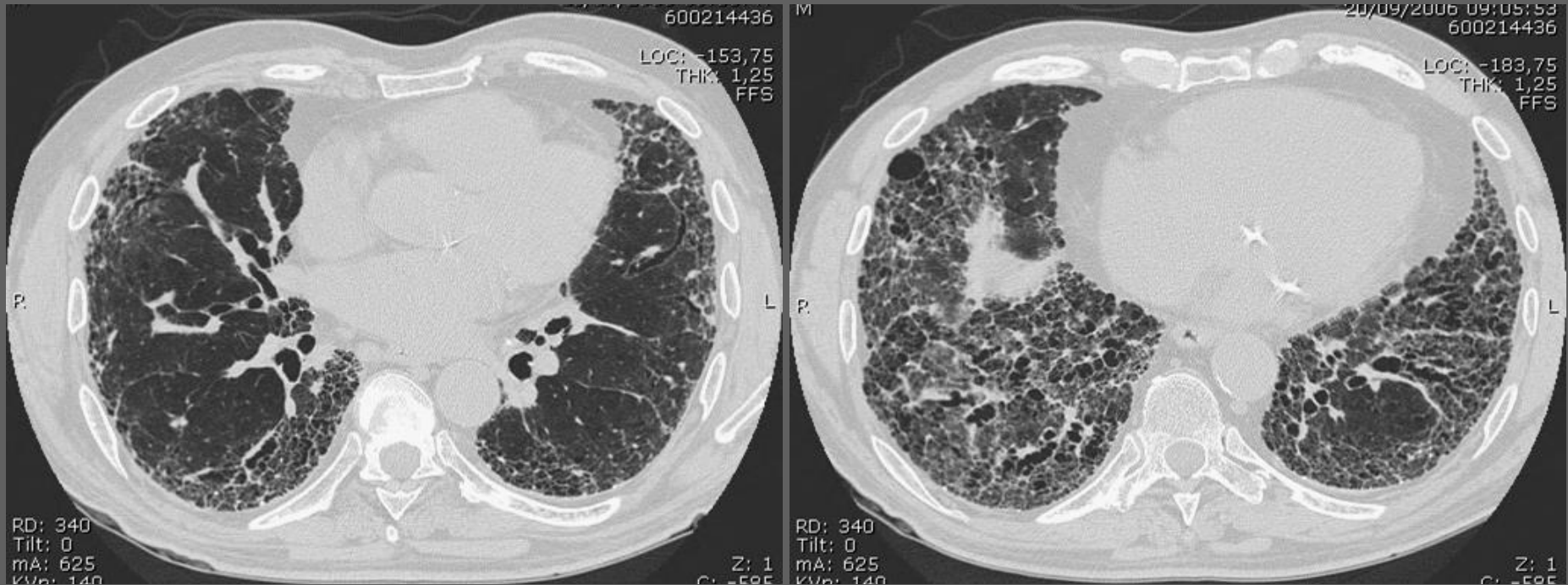
Modified from: Flaherty et al. *Am J Respir Crit Care Med* 2004; 170:904



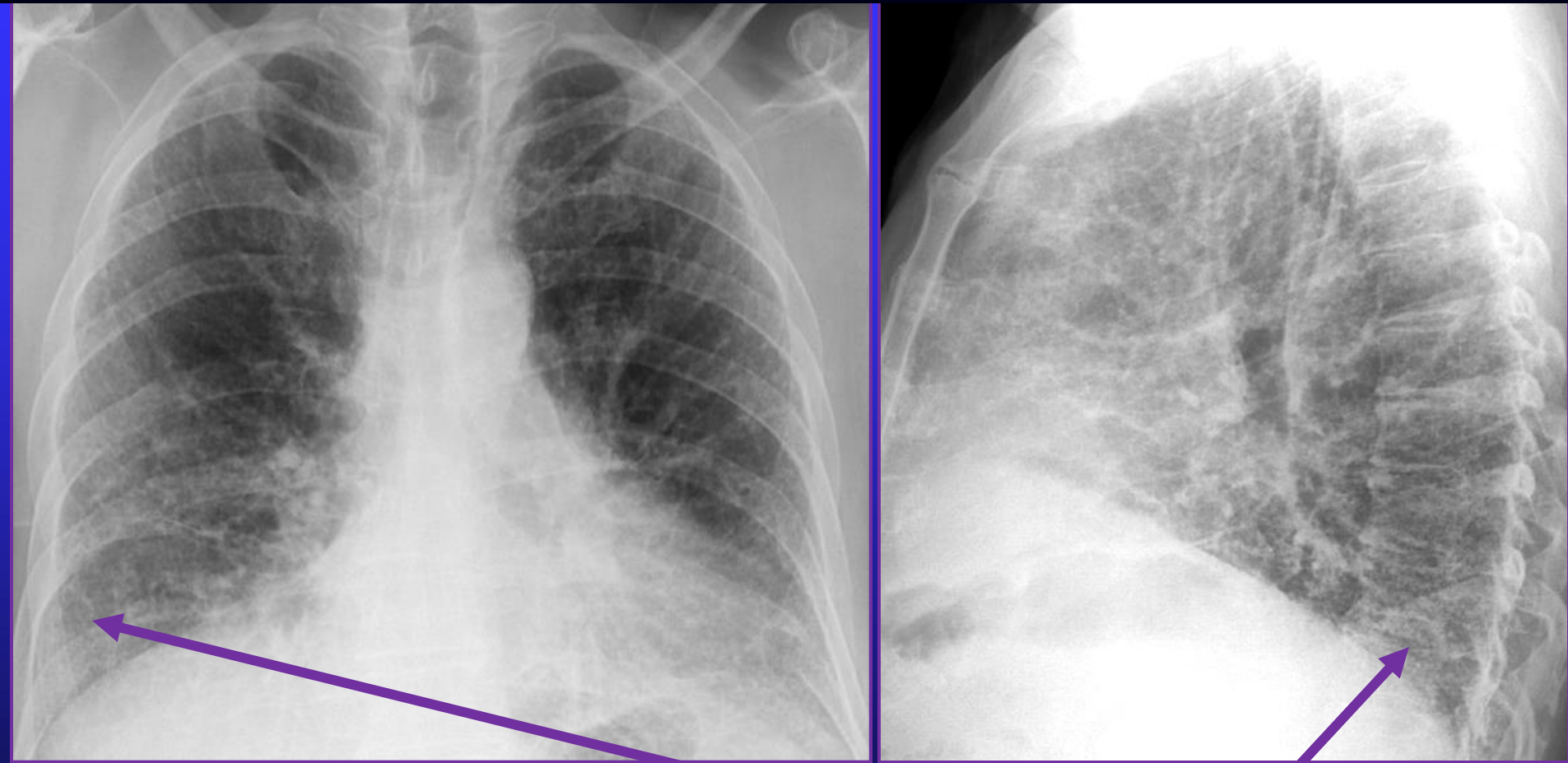
Requires pulmonologists, radiologists and pathologists working together

“The diagnosis of IPF *requires*:

- a) exclusion of other known causes of interstitial lung disease
- a) the presence of a UIP pattern on HRCT in patients not subjected to surgical lung biopsy
- a) specific combinations of HRCT and surgical lung biopsy pattern in patients subjected to surgical lung biopsy”



# *Chest radiograph in IPF*



Reduced lung volume

Basal and peripheral reticulation

*A normal chest x-ray does not exclude IPF*

# *Neglected evidence in idiopathic pulmonary fibrosis: from history to earlier diagnosis*

*Cordier JF, Cottin V Eur Respir J 2013;*

- IPF is a relatively recent disease linked to the tobacco epidemics
- IPF is a disease of ageing
- Earlier diagnosis of IPF could be obtained by recognizing the value of velcro crackles  
and
- by promoting the screening for IPF as a by-product of low-dose CT screening for lung cancer



# *Neglected evidence in idiopathic pulmonary fibrosis: from history to earlier diagnosis*

*Cordier JF, Cottin V Eur Respir J 2013;*

The syndrome of combined pulmonary fibrosis and emphysema strikingly recapitulates the three major respiratory consequences of cigarette smoking, namely pulmonary fibrosis, emphysema, and lung cancer.

fibrosis, suggesting that the development of ILD may result from an interaction between age, smoking and genetic factors.

# *Neglected evidence in idiopathic pulmonary fibrosis: from history to earlier diagnosis*

*Cordier JF, Cottin V Eur Respir J 2013; in press*

## ■ IPF is a disease of ageing

In an apparent paradox, familial interstitial pneumonia predominantly occurs at a younger age as compared to non-familial IPF.

Some clues as to why this may happen has arisen from the recent description of germline mutations in the genes *hTERT* and *hTR* associated to the telomerase complex

# *Neglected evidence in idiopathic pulmonary fibrosis: from history to earlier diagnosis*

*Cordier JF, Cottin V Eur Respir J 2013; in press*

We consider that presently only two approaches could realistically allow an earlier diagnosis of IPF:

Crackles are almost constant in patients with IPF. Although found in other ILDs and not specific for IPF, velcro crackles must prompt a thorough diagnostic process, including HRCT



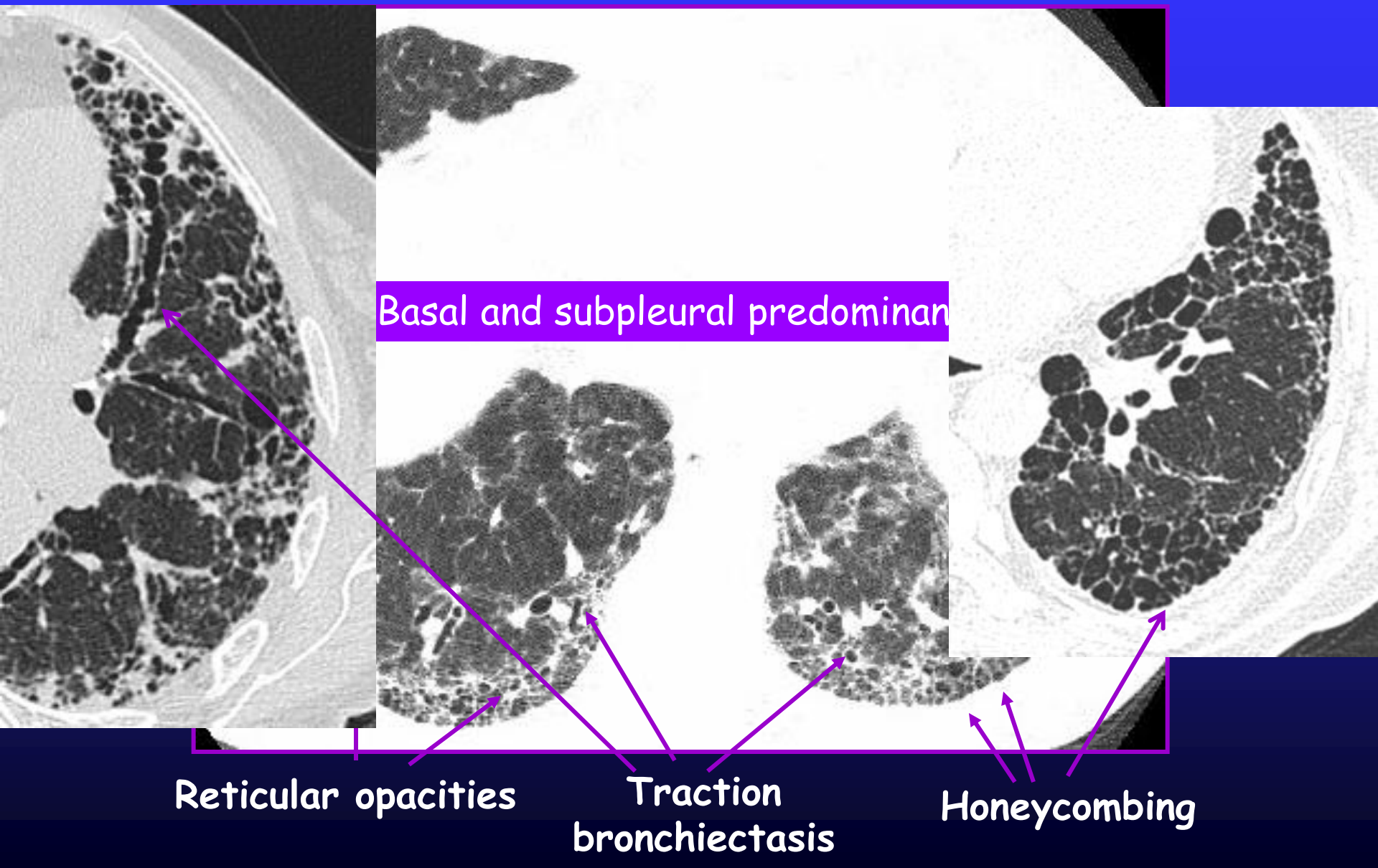
Typical exam is non-specific

Dry bi-basilar crackles most common finding

Inspiratory high-pitched squeaks can be seen with bronchiolitis

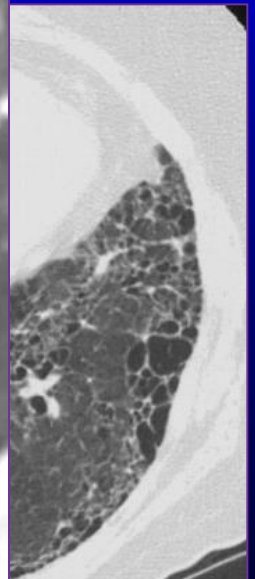
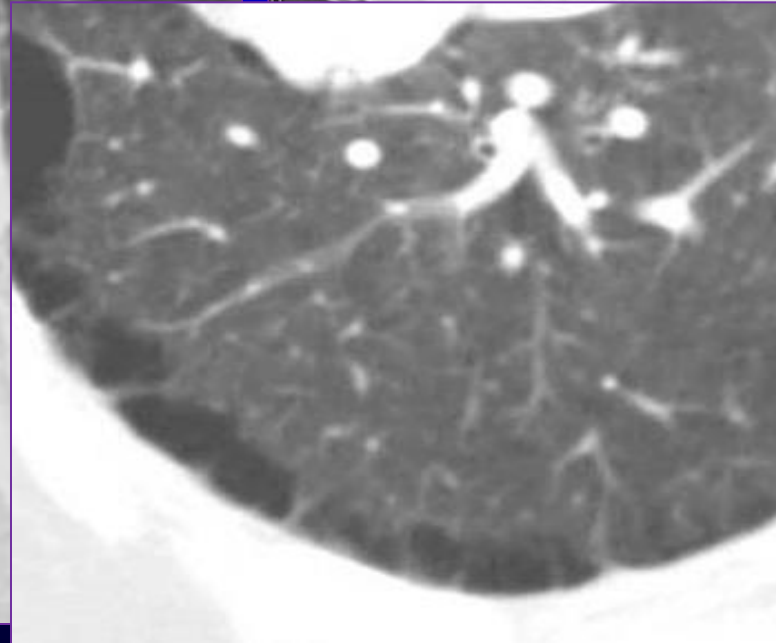
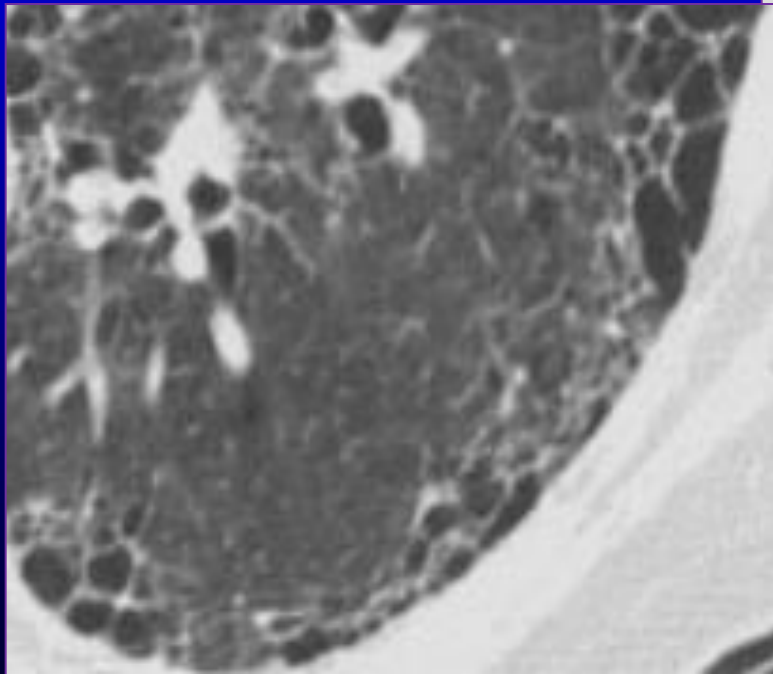
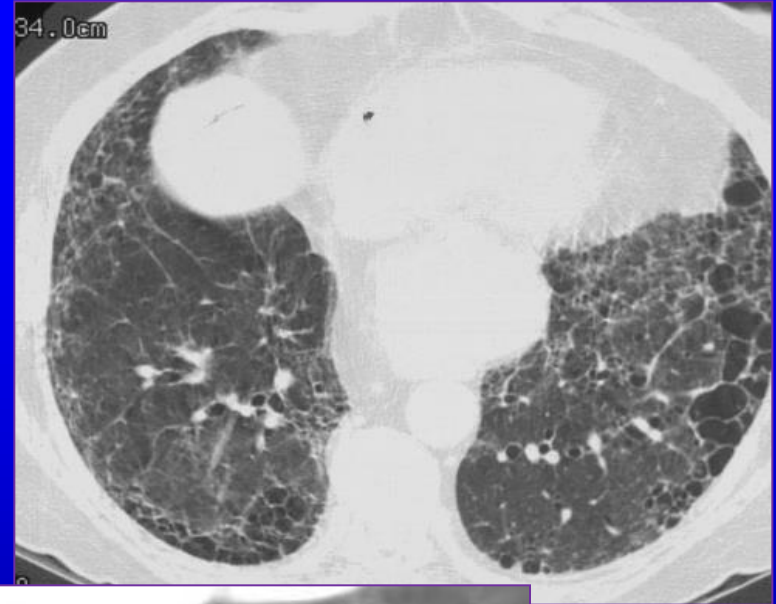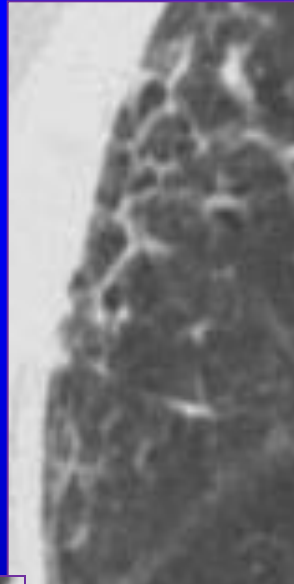
Skin, joint, or muscle findings should prompt evaluation for an underlying rheumatologic disorder

# *Classic IPF HRCT*



# HRCT

features of fibrosis,  
Intra-lobular and inter-lobular septal thickening,  
walled cysts representing  
honeycombing,  
may be associated traction  
bronchiectasis





# HRCT diagnosis of IPF

## IPF Findings

### UIP pattern (all four):

Sub-pleural, basal  
predominance

Reticular abnormality

Honeycombing with or without  
traction bronchiectasis

Absence of features listen as  
inconsistent with UIP

## Consider Alternate Diagnosis

### Possible UIP pattern (all three):

Subpleural, basal  
predominance

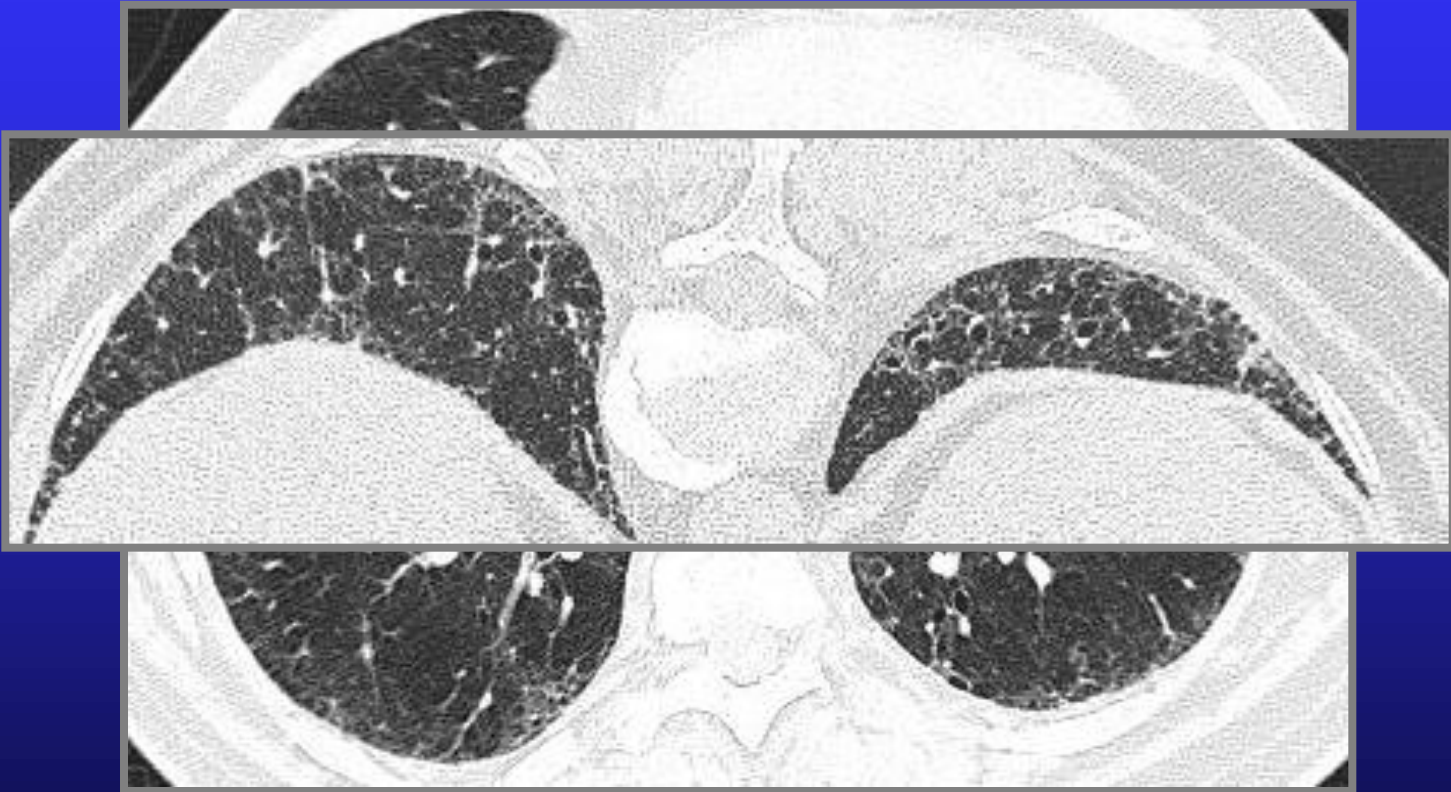
Reticular abnormality

Absence of features listen as  
inconsistent with UIP

***Am J Respir Crit Care Med 2011; 183: 788-824***



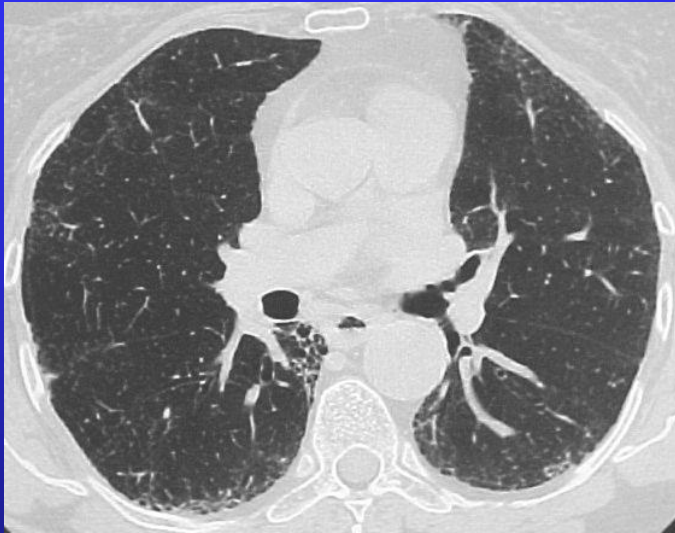
# *Use of prone Imaging*



# *UIP: progression of fibrosis on CT*

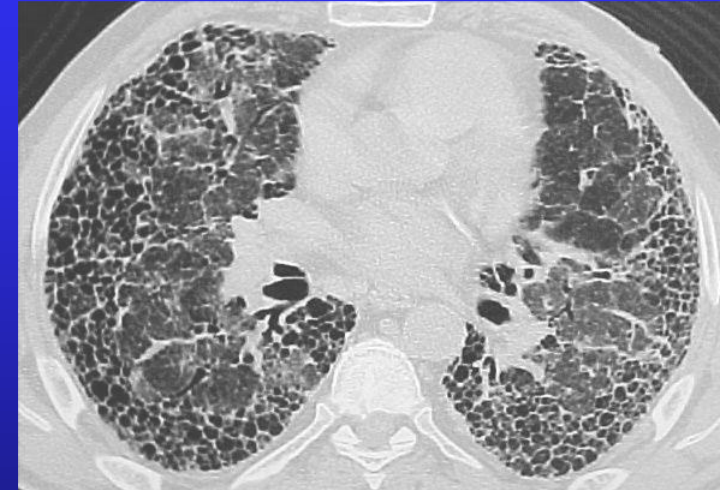Early:

Reticular



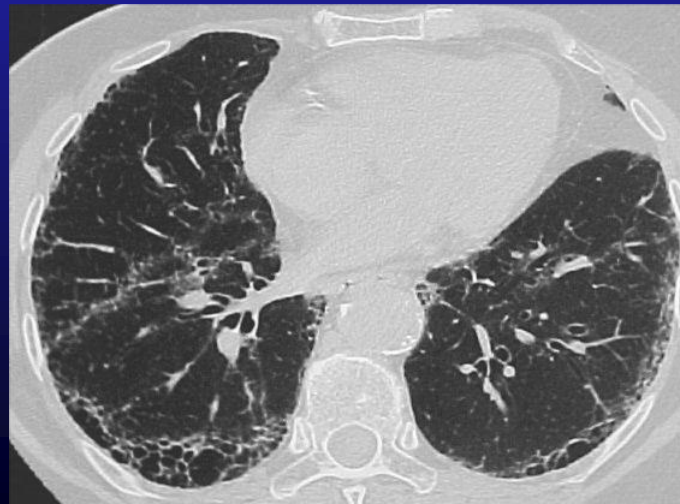
Late:

Diffuse honeycombing



Midcourse:

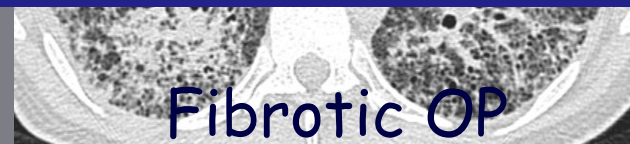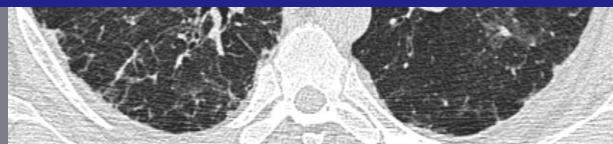
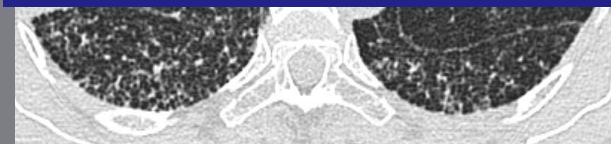Subpleural  
honeycombing



## Inconsistent with UIP pattern (any of the seven):

- Upper or mid-lung predominance
- Peribronchovascular predominance
- Extensive ground glass abnormality (extent > reticular abnormality)
- Profuse micronodules (bilateral, predominantly upper lobes)
- Discrete cysts (multiple, bilateral, away from areas of honeycombing)
- Diffuse mosaic attenuation/air-trapping (bilateral, in three or more lobes)
- Consolidation in bronchopulmonary segment(s)/lobe(s)

***Am J Respir Crit Care Med 2011; 183: 788-824***



Fibrotic OP

## *Key conclusion*

- Typical HRCT features of IPF in association with a compatible clinical profile obviate surgical biopsy

***BUT***

*High-Resolution Computed Tomography  
and the Many Faces of Idiopathic Pulmonary  
Fibrosis*

# *The spectrum of atypical HRCT appearances in IPF*

- Exploration of biopsy-proven IPF (n=55)
- As expected, a high prevalence of atypical HRCT findings (n=34, 62%), as judged by three observers
- Alternative HRCT diagnoses analysed

## *Atypical HRCT appearances in IPF*

- Alternative first choice diagnoses were NSIP (53%), chronic HP (12%), sarcoidosis (9%), “unclassifiable” (23%)
- Cases with atypical appearances had the same IPF-like outcome as those with typical HRCT appearances

# Am J Respir Crit Care Med 2011; 183: 788-824

**TABLE 5. HISTOPATHOLOGICAL CRITERIA FOR UIP PATTERN**

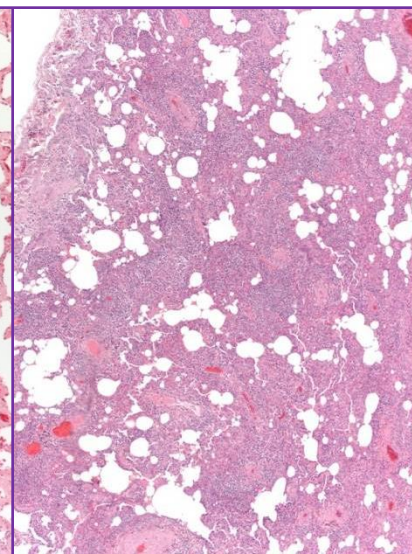
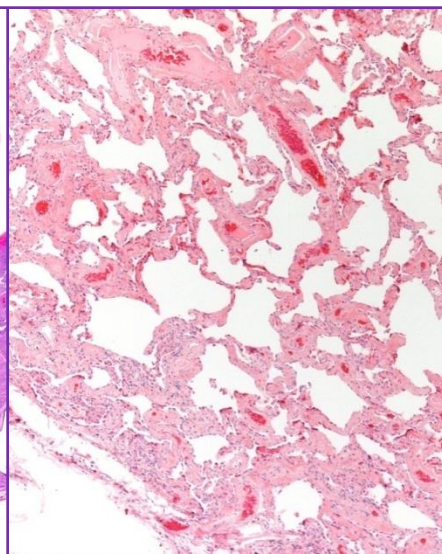
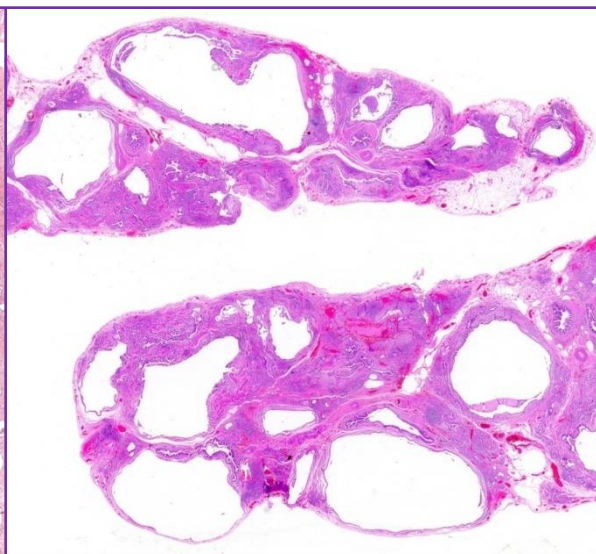
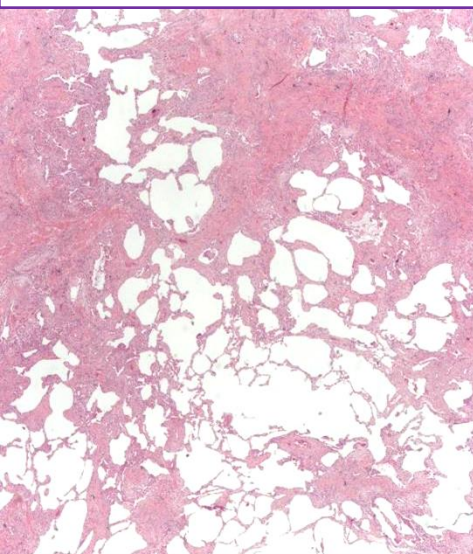
UIP Pattern (All Four Criteria)	Probable UIP Pattern	Possible UIP Pattern (All Three Criteria)	Not UIP Pattern (Any of the Six Criteria)
<ul style="list-style-type: none"> <li>• Evidence of marked fibrosis/ architectural distortion, <math>\pm</math> honeycombing in a predominantly subpleural/ paraseptal distribution</li> <li>• Presence of patchy involvement of lung parenchyma by fibrosis</li> <li>• Presence of fibroblast foci</li> <li>• Absence of features against a diagnosis of UIP suggesting an alternate diagnosis (see fourth column)</li> </ul>	<ul style="list-style-type: none"> <li>• Evidence of marked fibrosis / architectural distortion, <math>\pm</math> honeycombing</li> <li>• Absence of either patchy involvement or fibroblastic foci, but not both</li> <li>• Absence of features against a diagnosis of UIP suggesting an alternate diagnosis (see fourth column)</li> </ul> <p>OR</p> <ul style="list-style-type: none"> <li>• Honeycomb changes only<sup>‡</sup></li> </ul>	<ul style="list-style-type: none"> <li>• Patchy or diffuse involvement of lung parenchyma by fibrosis, with or without interstitial inflammation</li> <li>• Absence of other criteria for UIP (see UIP PATTERN column)</li> <li>• Absence of features against a diagnosis of UIP suggesting an alternate diagnosis (see fourth column)</li> </ul>	<ul style="list-style-type: none"> <li>• Hyaline membranes*</li> <li>• Organizing pneumonia*<sup>†</sup></li> <li>• Granulomas<sup>†</sup></li> <li>• Marked interstitial inflammatory cell infiltrate away from honeycombing</li> <li>• Predominant airway centered changes</li> <li>• Other features suggestive of an alternate diagnosis</li> </ul>



# Am J Respir Crit Care Med 2011; 183: 788-824

**TABLE 5. HISTOPATHOLOGICAL CRITERIA FOR UIP PATTERN**

UIP Pattern (All Four Criteria)	Probable UIP Pattern	Possible UIP Pattern (All Three Criteria)	Not UIP Pattern (Any of the Six Criteria)
<ul style="list-style-type: none"> <li>• Evidence of marked fibrosis/ architectural distortion, <math>\pm</math> honeycombing in a predominantly subpleural/ paraseptal distribution</li> <li>• Presence of patchy involvement of lung parenchyma by fibrosis</li> <li>• Presence of fibroblast foci</li> <li>• Absence of features against a diagnosis of UIP suggesting an alternate diagnosis (see fourth column)</li> </ul>	<ul style="list-style-type: none"> <li>• Evidence of marked fibrosis / architectural distortion, <math>\pm</math> honeycombing</li> <li>• Absence of either patchy involvement or fibroblastic foci, but not both</li> <li>• Absence of features against a diagnosis of UIP suggesting an alternate diagnosis (see fourth column)</li> </ul> <p>OR</p> <ul style="list-style-type: none"> <li>• Honeycomb changes only<sup>‡</sup></li> </ul>	<ul style="list-style-type: none"> <li>• Patchy or diffuse involvement of lung parenchyma by fibrosis, with or without interstitial inflammation</li> <li>• Absence of other criteria for UIP (see UIP PATTERN column)</li> <li>• Absence of features against a diagnosis of UIP suggesting an alternate diagnosis (see fourth column)</li> </ul>	<ul style="list-style-type: none"> <li>• Hyaline membranes<sup>*</sup></li> <li>• Organizing pneumonia<sup>*†</sup></li> <li>• Granulomas<sup>†</sup></li> <li>• Marked interstitial inflammatory cell infiltrate away from honeycombing</li> <li>• Predominant airway centered changes</li> <li>• Other features suggestive of an alternate diagnosis</li> </ul>






HRCT Pattern	Surgical Lung Biopsy Pattern (when performed)	Diagnosis of IPF?
UIP	<b>UIP</b> Probable UIP Possible UIP Non-classifiable fibrosis	<b>YES</b>
	Not UIP	No
Possible UIP	<b>UIP</b> Probable UIP	<b>YES</b>
	Possible UIP Non-classifiable fibrosis	<i>Probable</i>
	Not UIP	No
Inconsistent with UIP	<b>UIP</b>	<i>Possible</i>
	Probable UIP Possible UIP Non-classifiable fibrosis Not UIP	No

# *Risks of biopsy*

- ◆ Morbidity increases with age
- ◆ Co-morbidity a major constraint
- ◆ In many patients, disease severity does not allow biopsy
- ◆ In severe disease, a biopsy sometimes less useful


Early mortality was associated solely with the severity of lung function impairment at presentation, but mortality after 2 years of follow-up was primarily linked to the histopathologic diagnosis

Survival



- Risk increases as gas transfer falls below 30-35%
- Prognostic value diminishes as gas transfer falls below 30-35%

Per



Time (months)

## *Usefulness of BAL in diagnosis of IPF:*

*Should BAL cellular analysis be performed in the diagnostic evaluation of suspected IPF?*

The most important application of BAL is in the exclusion of chronic HP; prominent lymphocytosis (>40%) should suggest the diagnosis

*Recommendation:* BAL cellular analysis should not be performed in the diagnostic evaluation of IPF in the majority of patients, but may be appropriate in a minority (weak recommendation, low-quality evidence)

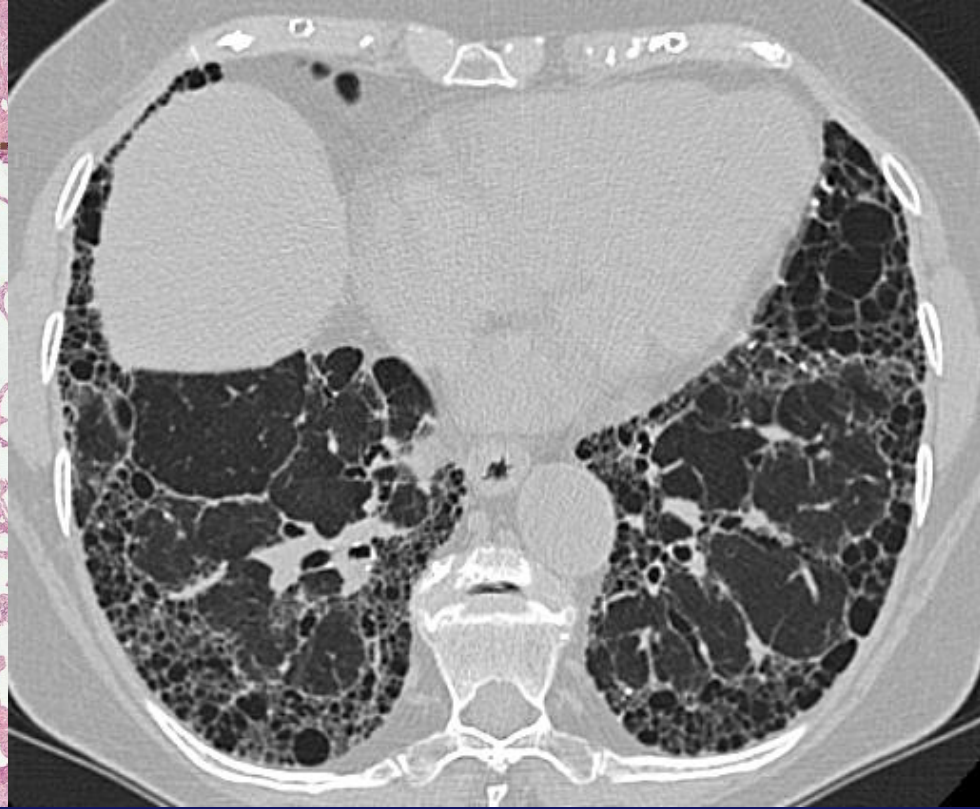
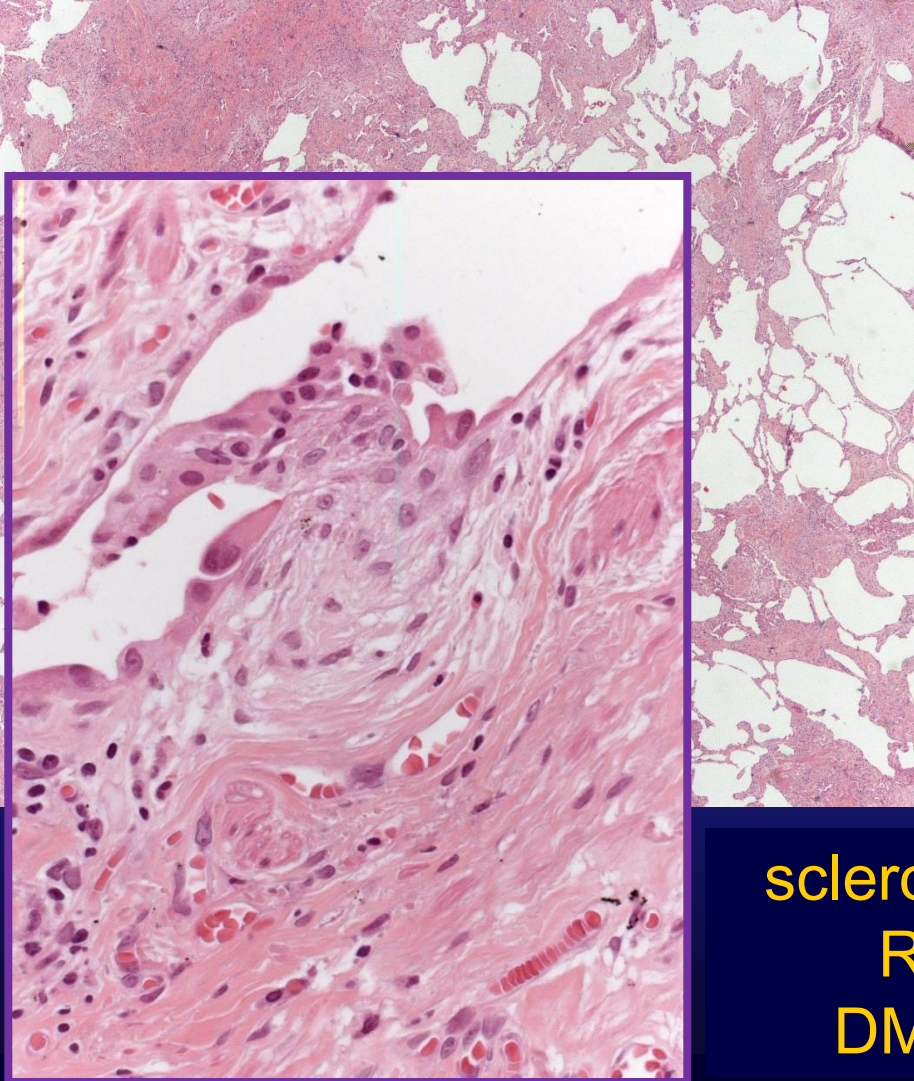
***Am J Respir Crit Care Med 2011; 183: 788-824***

## *Should TBB be used in the evaluation of suspected IPF?*

In cases requiring histopathology, the specificity and positive predictive value of UIP pattern identified by TBB has not been rigorously studied. While TBB specimens may show all the histologic features of UIP, the sensitivity and specificity of this approach for the diagnosis for UIP pattern is unknown.

*Recommendation:* TBB should not be used in the evaluation of IPF in the majority of patients, but may be appropriate in a minority (weak recommendation, low-quality evidence)

# *Usual interstitial pneumonia*



scleroderma  
RhA  
DM/PM



# *Should serologic testing for connective tissues diseases be used in the evaluation of suspected IPF?*

- CTD can present with a UIP pattern
- ILD has been described as the sole clinical manifestation of these conditions
- ILD can precede the overt manifestation of a specific CTD

*Recommendation: serologic testing for CTD should be performed in the evaluation of IPF in the majority of patients, but may be appropriate in a minority (weak recommendation, very low-quality evidence)*

***Am J Respir Crit Care Med 2011; 183: 788-824***

# *Serologic tests can help exclude other conditions*

Connective tissue diseases

ESR

ANA

CCP (for RA)

CK

Aldolase

Anti-myositis panel with Jo-1 antibody

ENA panel

- Scl-70
- Ro (SSA)
- La (SSB)
- Smith
- RNP

Hypersensitivity pneumonitis

Hypersensitivity panel (if exposure history)



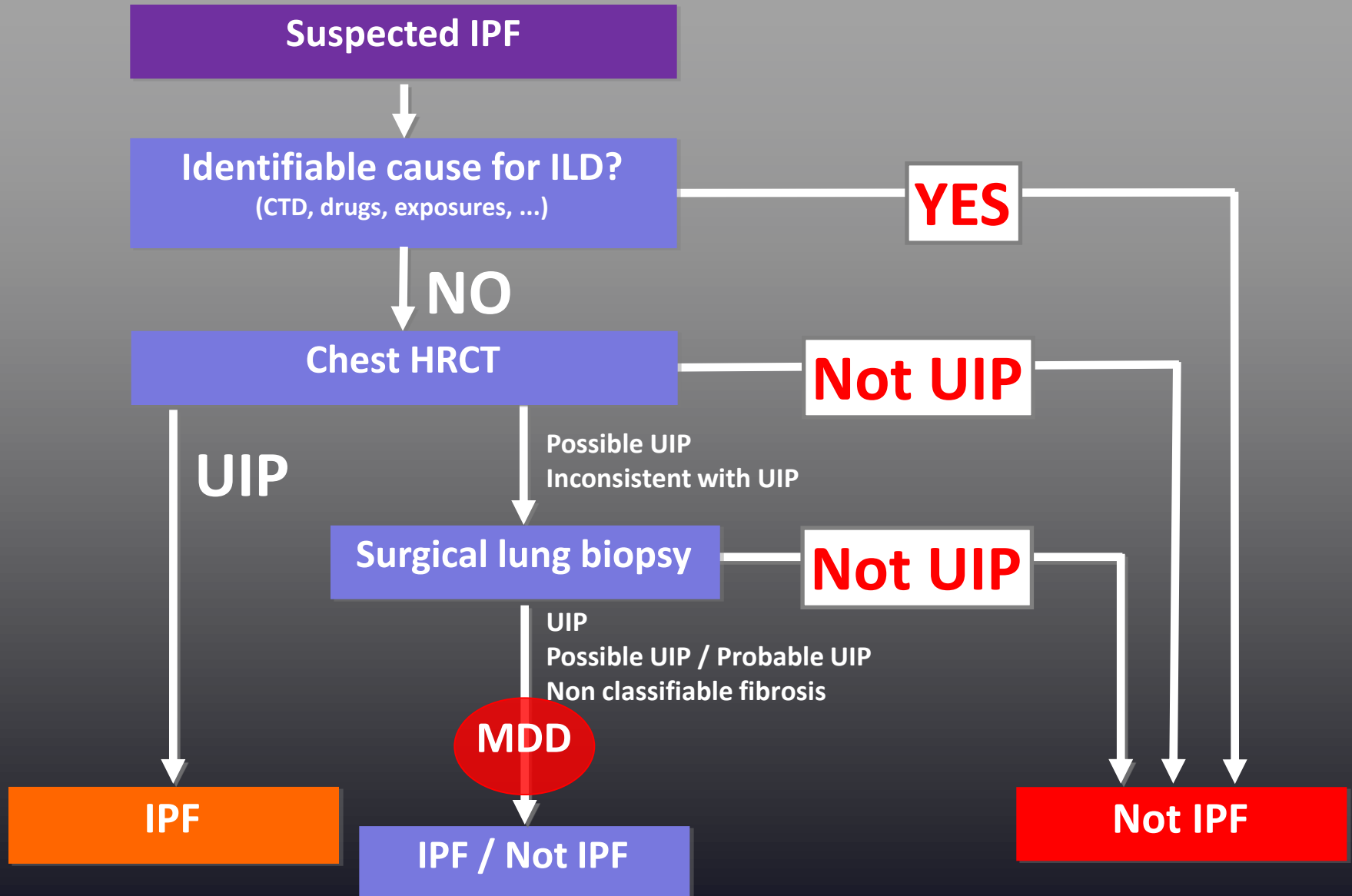
# *What's the problem?*

- ◆ It is not uncommon for pulmonologist to find patients with IP who are supposed to have a systemic autoimmune disease
- ◆ Within current classification schemes, many of these patients are labeled as idiopathic by default
- ◆ Despite the recognition that IP may be the *forme fruste* presentation of CTD, current classification criteria do not allow a CTD designation for ILD alone

# *Why is important to discover an occult CTD?*

- ◆ For disease prognosis
- ◆ For appropriate therapeutic approach
- ◆ For a search of additional system involvement or underlying malignancy
- ◆ For specific complications
- ◆ Is lung biopsy indicated?

# Diagnostic algorithm for IPF



## *Should a multi-disciplinary discussion be used in the evaluation of suspected IPF?*

The diagnosis of IPF is, by definition, multidisciplinary.  
Proper communication between the various disciplines involved in the diagnosis of IPF (pulmonary, radiology, pathology) has been shown to improve inter-observer agreement among experienced clinical experts as to the ultimate diagnosis

*Recommendation: we recommend that a multi-disciplinary discussion should be used in the evaluation of IPF (strong recommendation, low-quality evidence)*

*Timely referral to ILD experts is encouraged*

***Am J Respir Crit Care Med 2011; 183: 788-824***

# *Conclusions*

- ◆ The early recognition of IPF starts with a high level of clinical suspicion
- ◆ The approach to the diagnosis of IPF requires a multi-disciplinary effort (pulmonologist, radiologist, and pathologist)
- ◆ Differentiating IPF from other ILDs can direct the management and predict the prognosis of these patients

# *Conclusions*

- ◆ In some patients, lung involvement precedes other systemic manifestations, making the distinction between IIP and lung involvement of CTD impossible
- ◆ An association of IIP with CTD should be vigorously searched, not only at time of diagnosis but also during follow-up

# *Conclusions*

- ◆ It is important to look for additional minor/minimal abnormalities (clinical, radiological, histological) that may help in diagnosis of occult CTD or chronic HP
- ◆ IPF can be diagnosed on HRCT in the majority of cases but a crucial sub-group have very atypical HRCT appearances
- ◆ Perform an accurate diagnosis of ILD and IPF is very difficult and complex!